

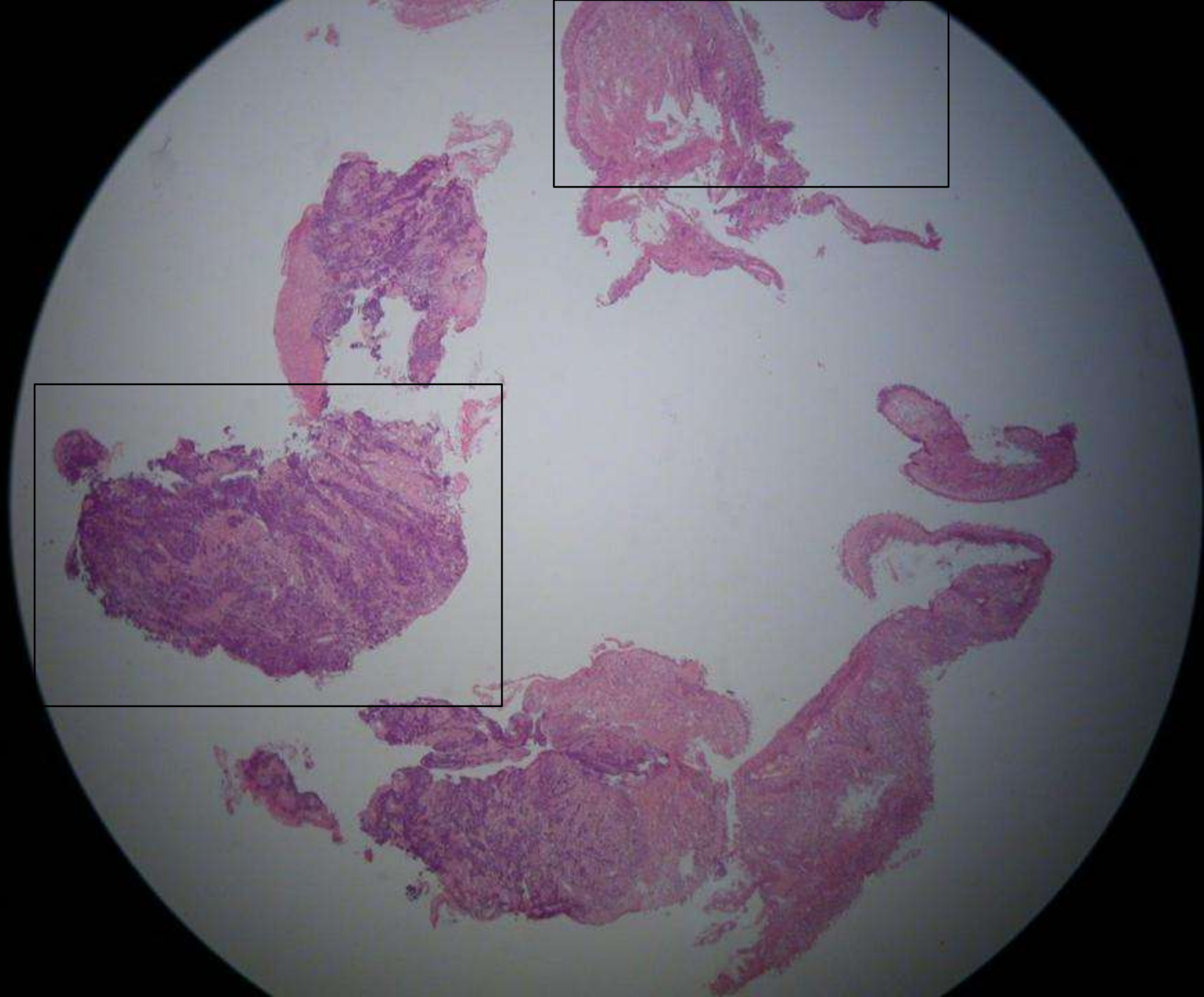
Lung tumor

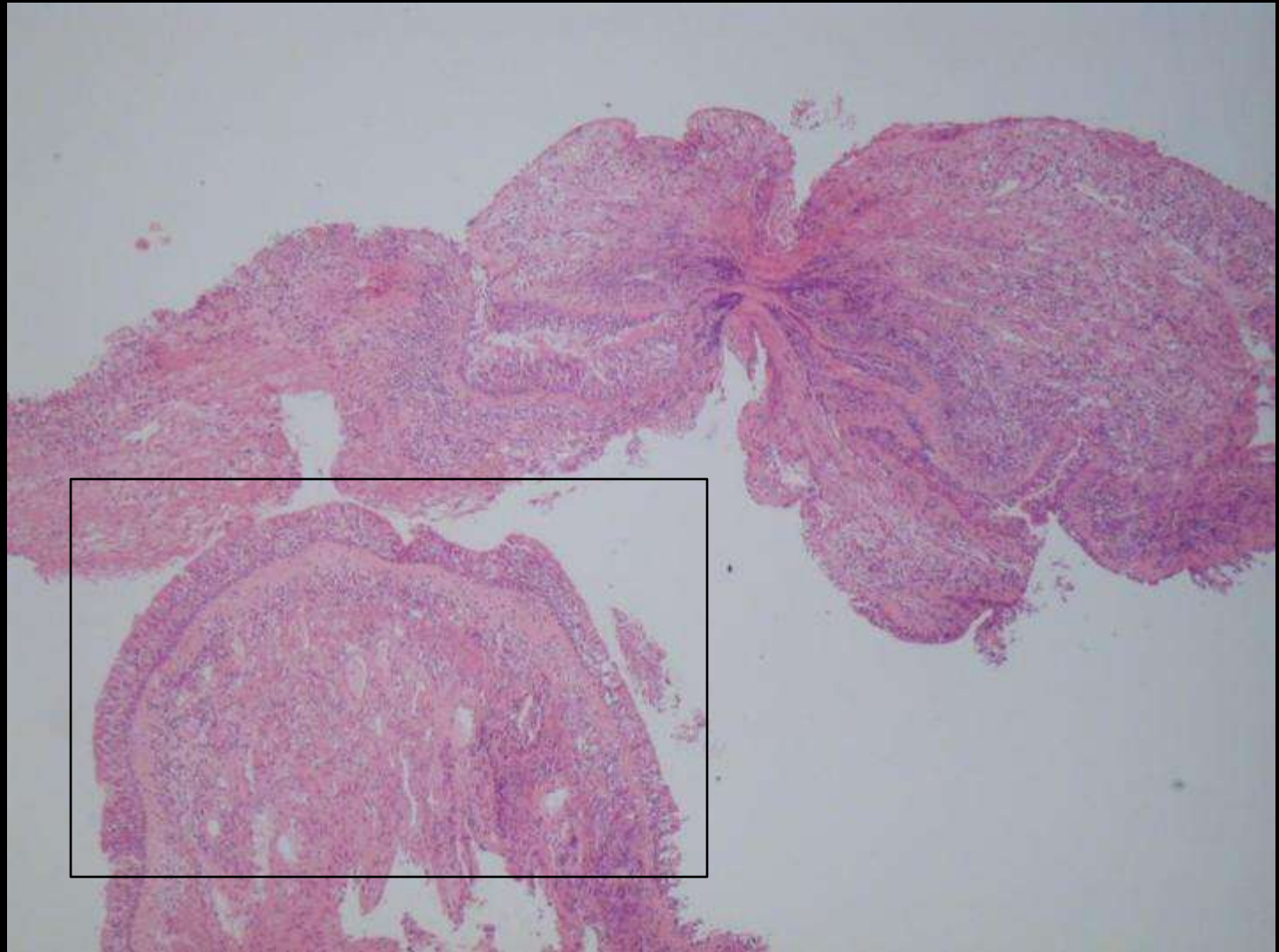
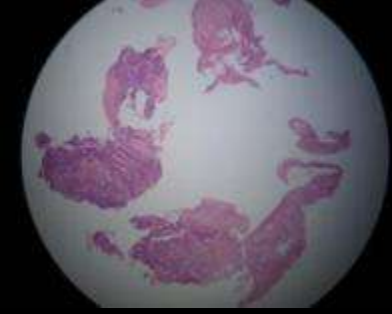
Endoscopic biopsy

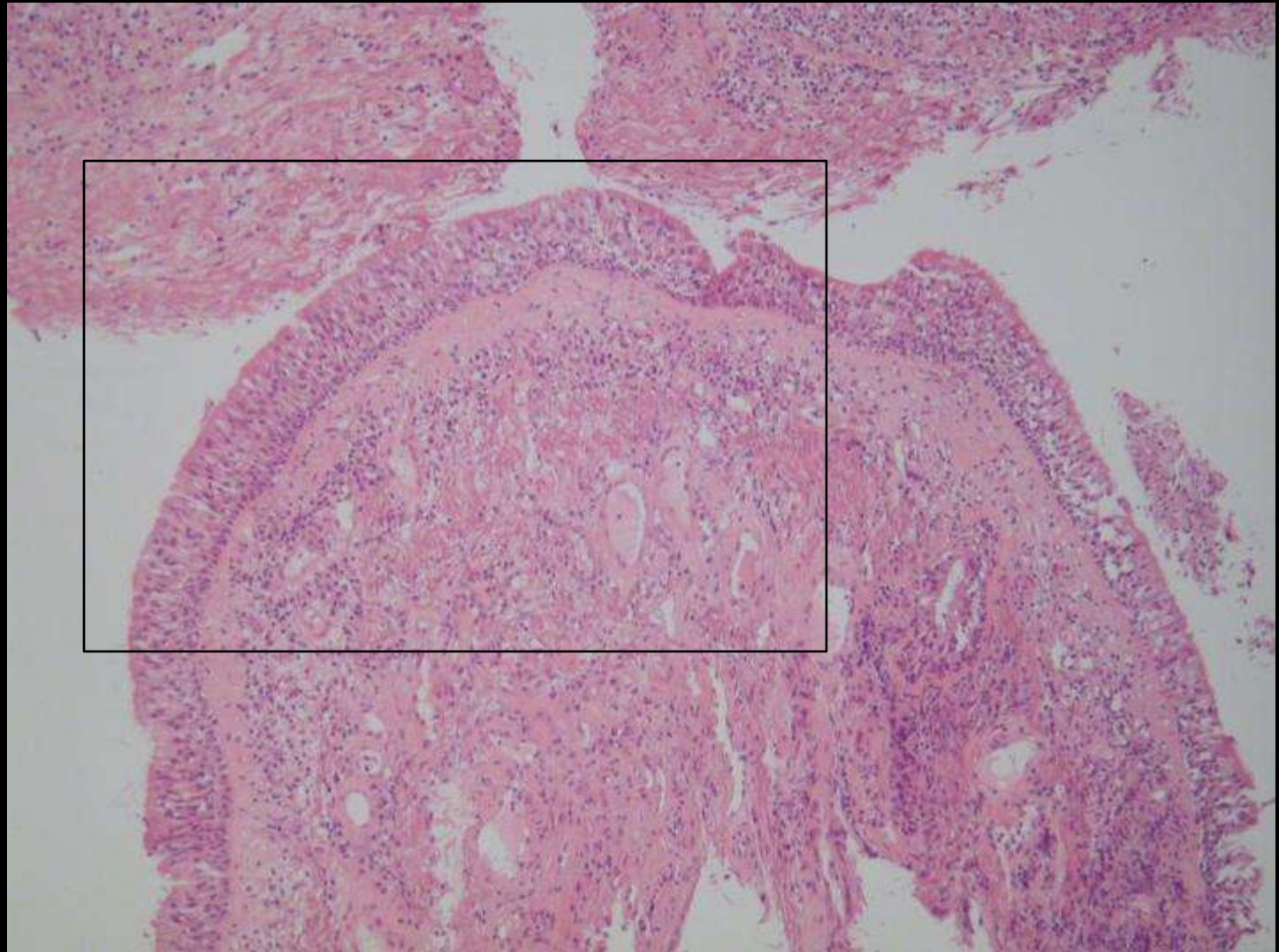
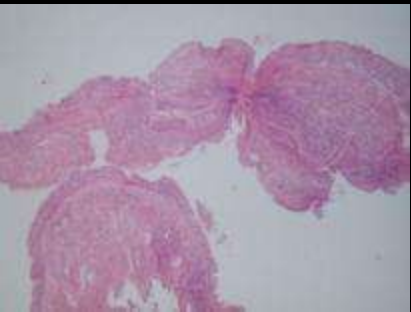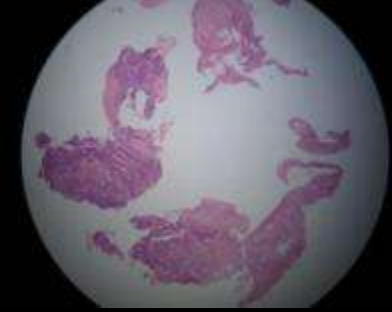
Gérard ABADJIAN

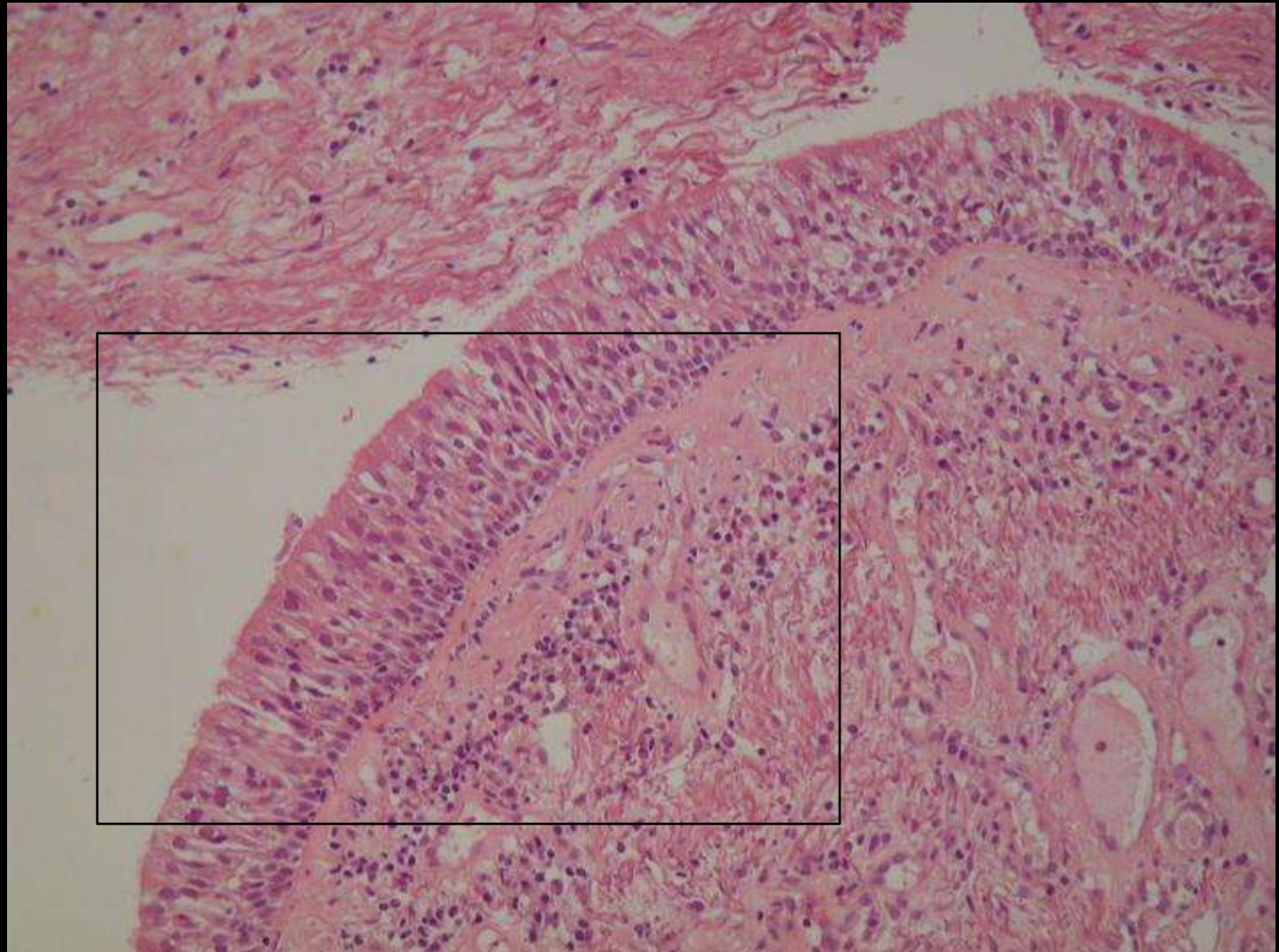
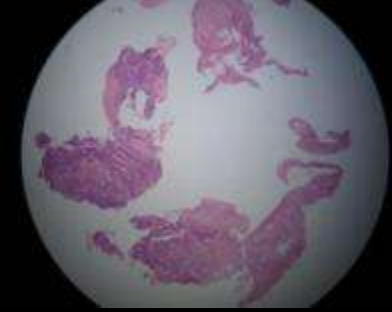
May 2008

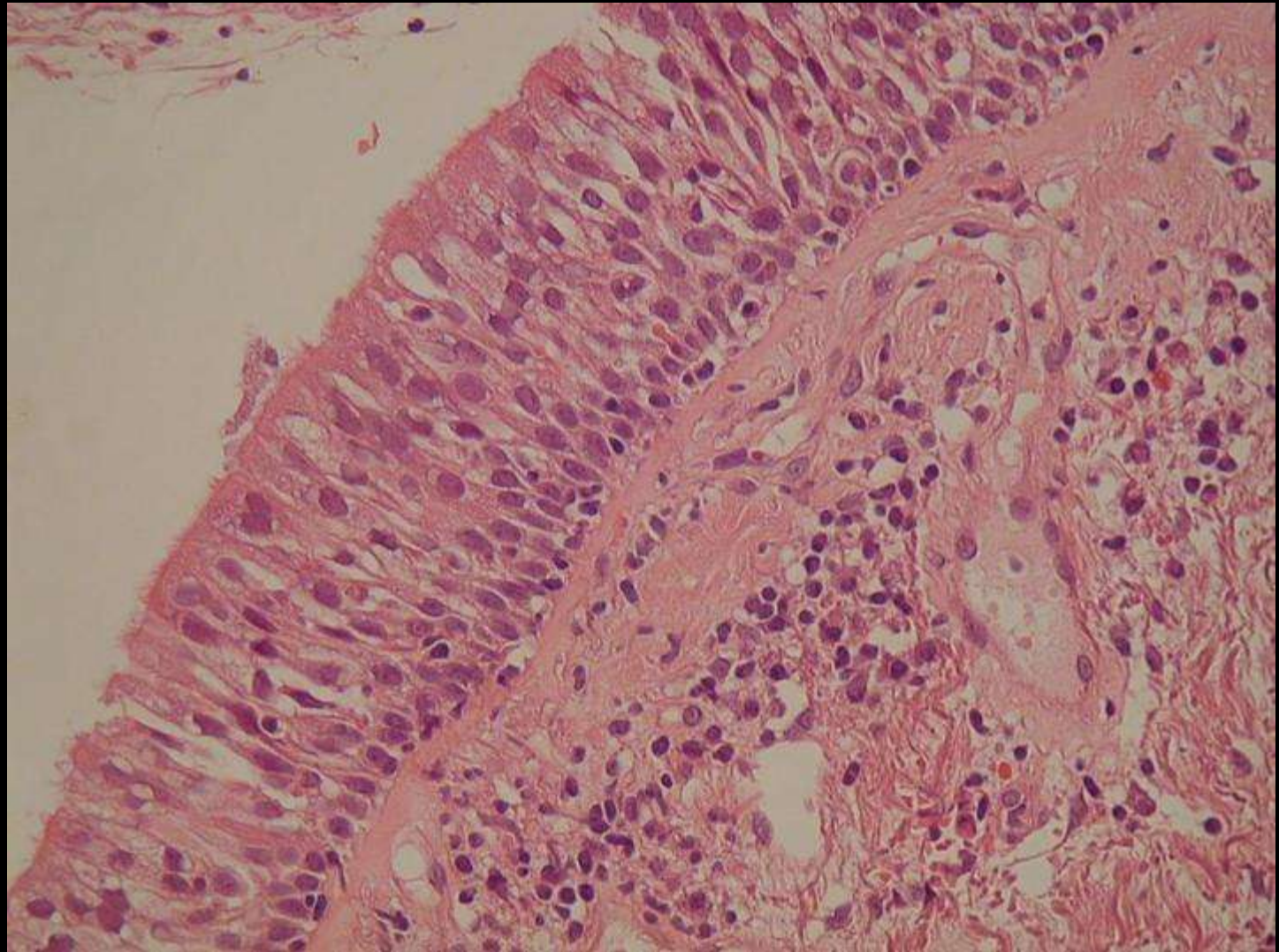
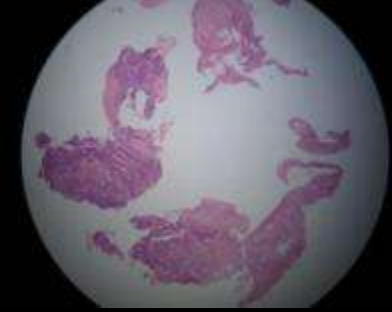
Diagnosis in the last slide

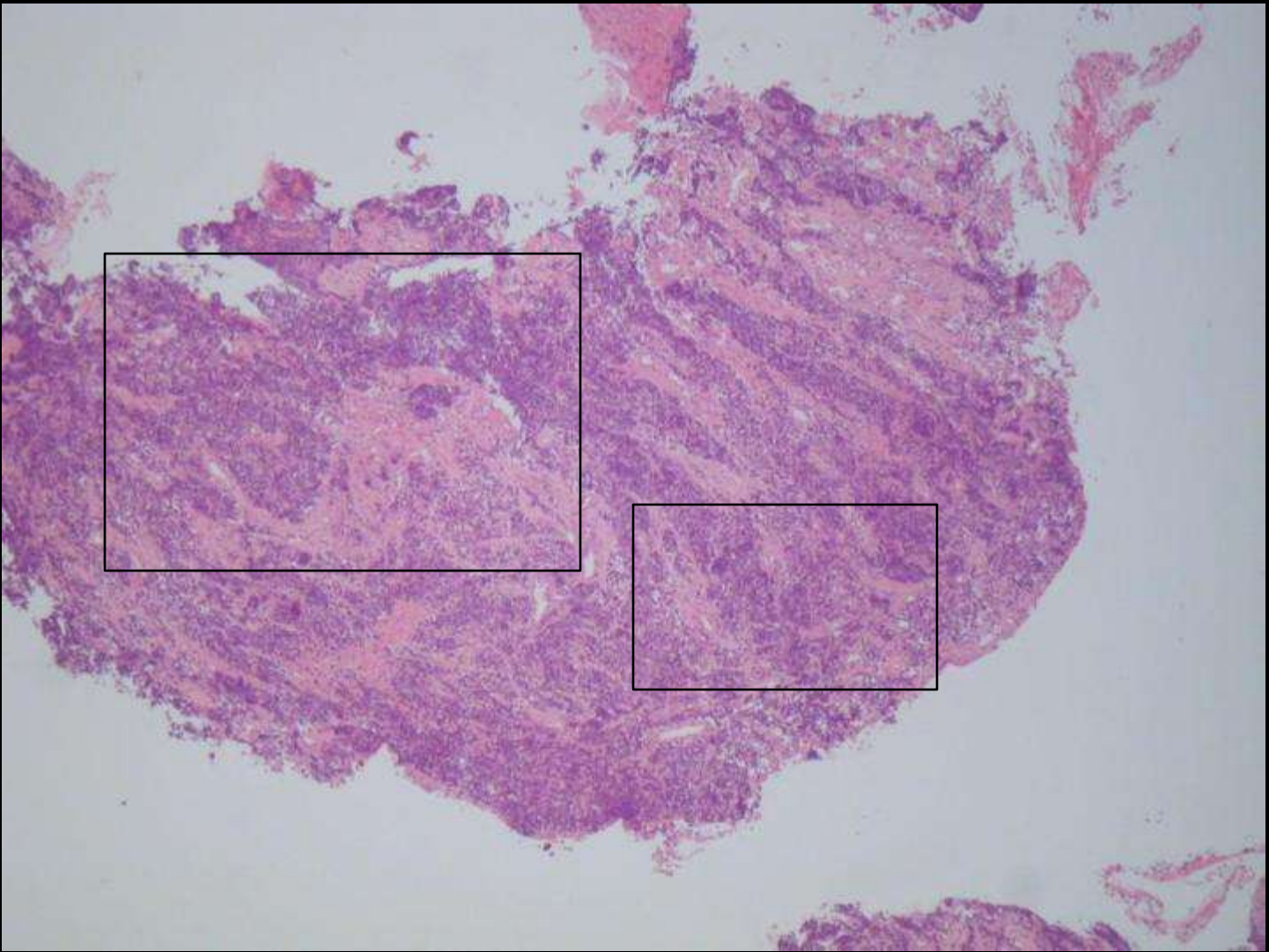
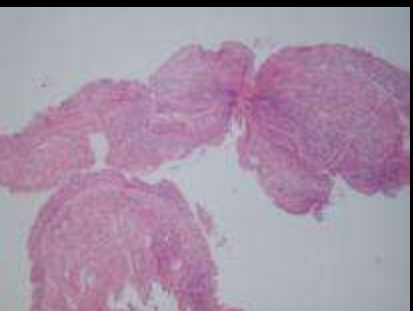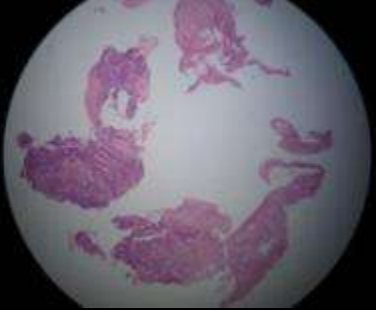


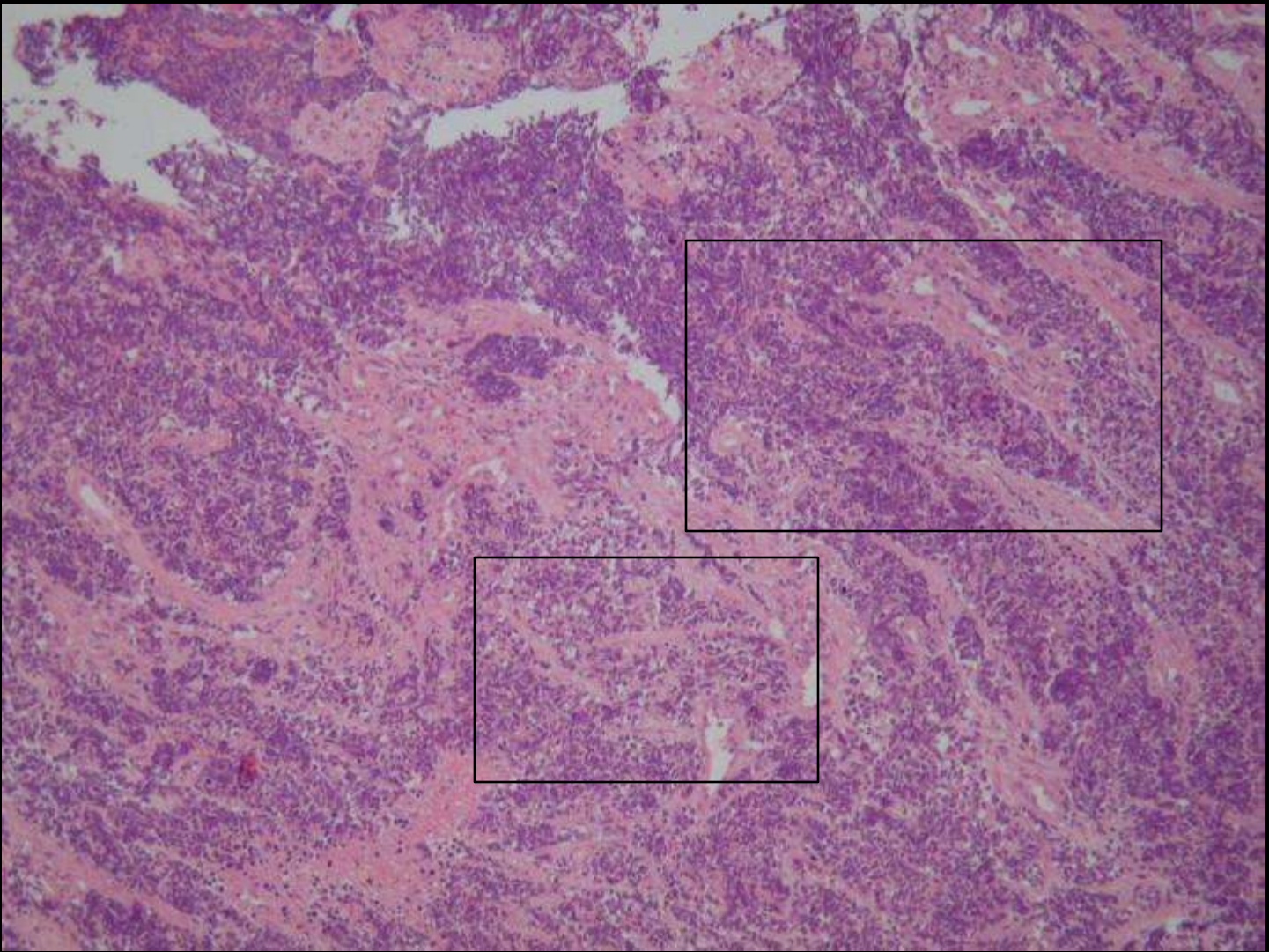
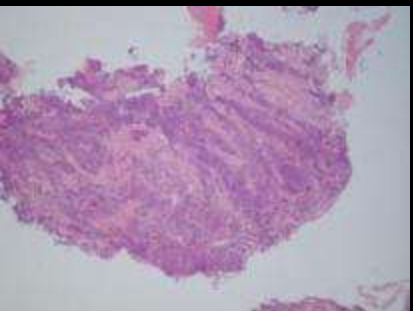
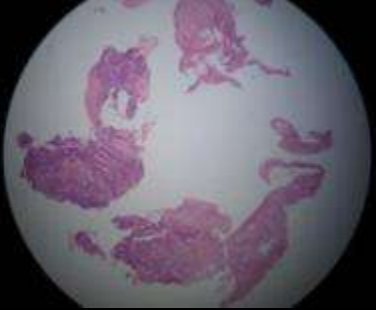


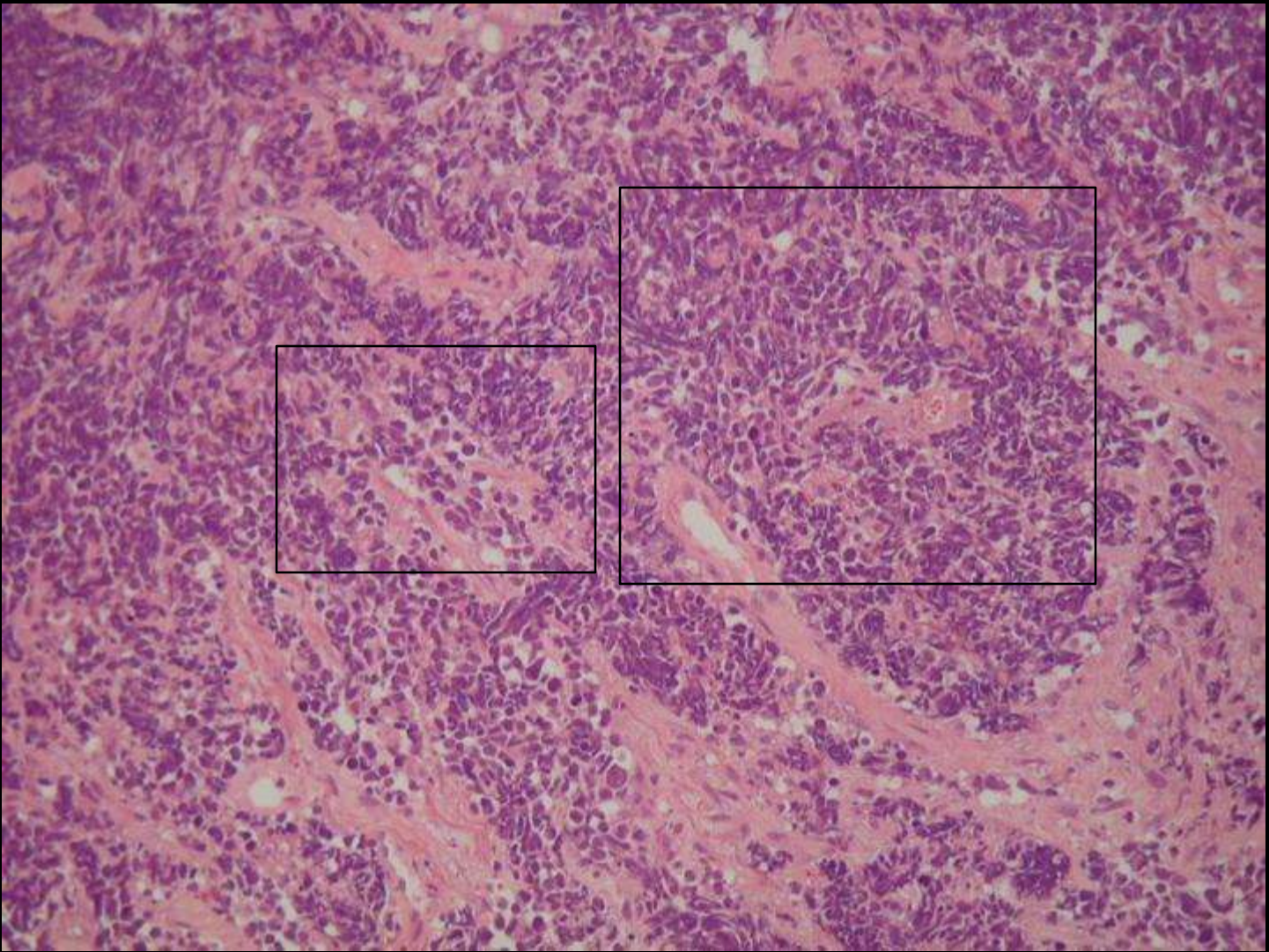
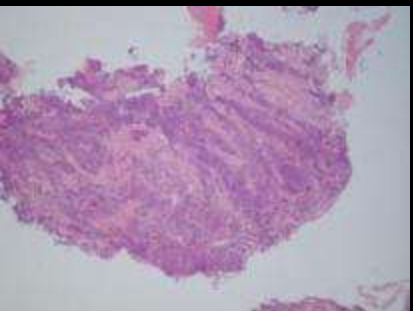
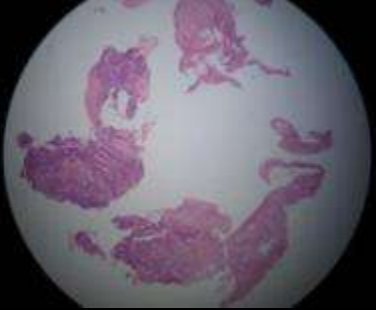


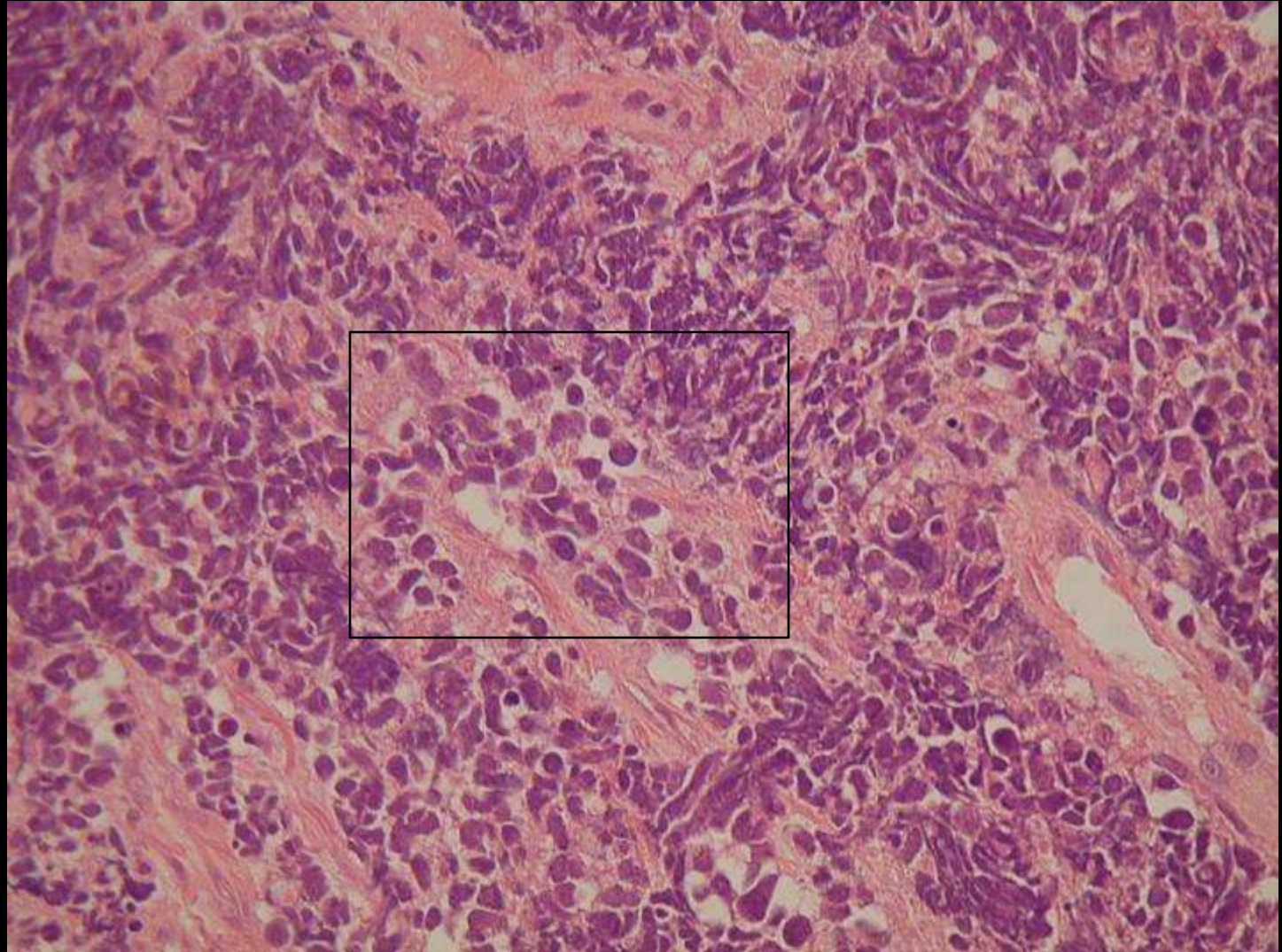
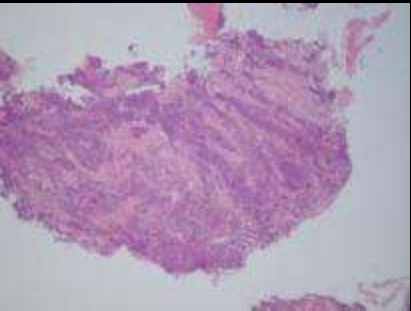
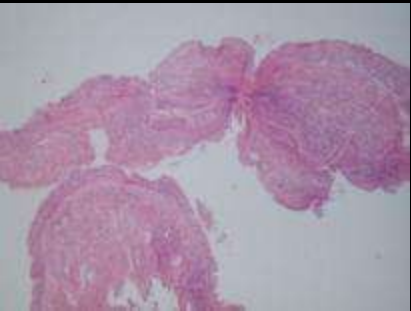
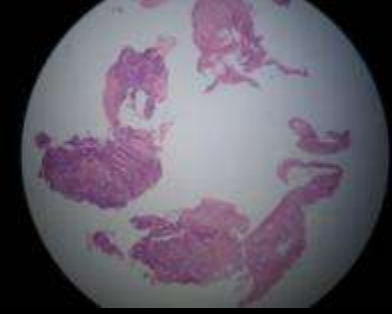


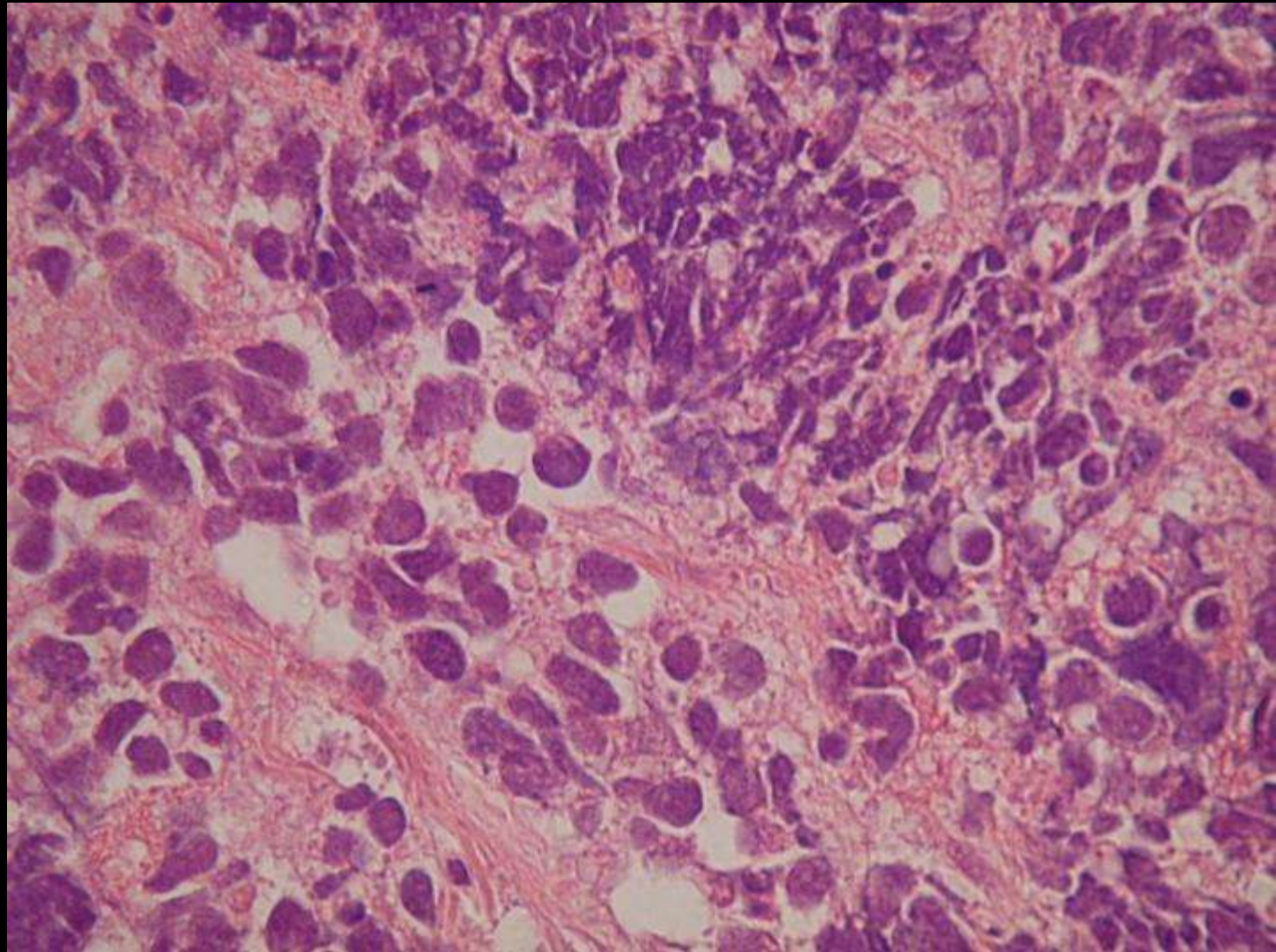
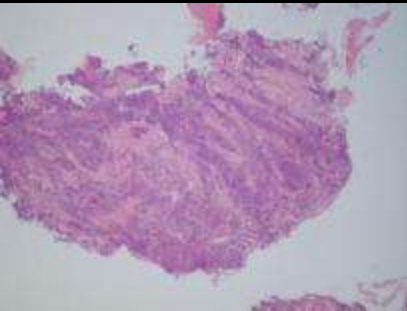
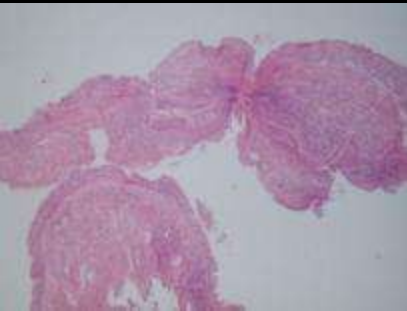
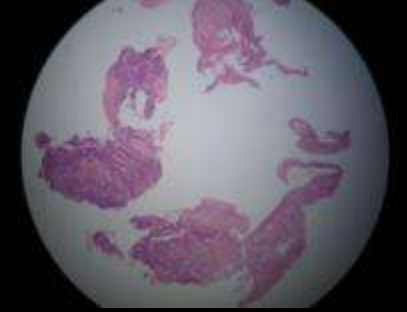












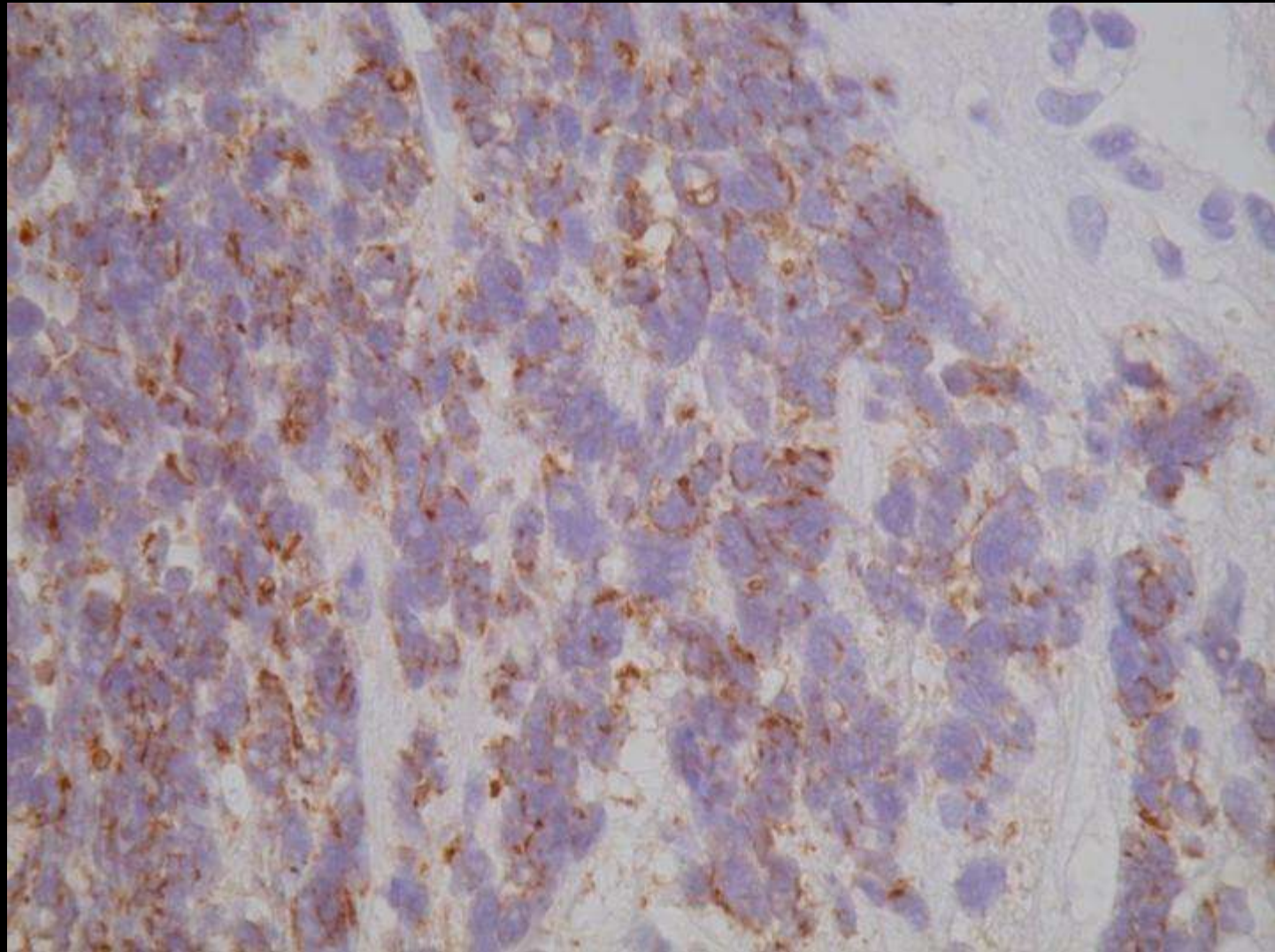
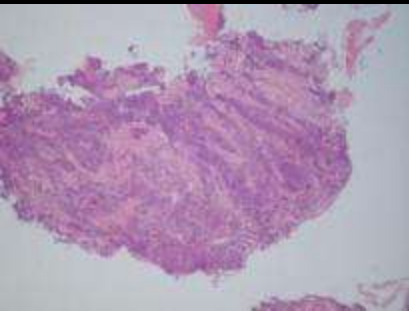
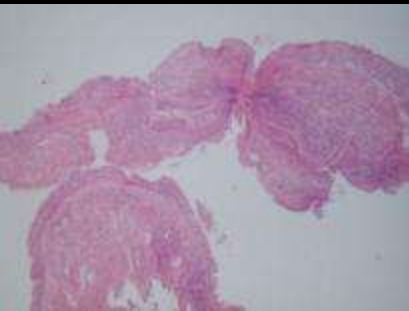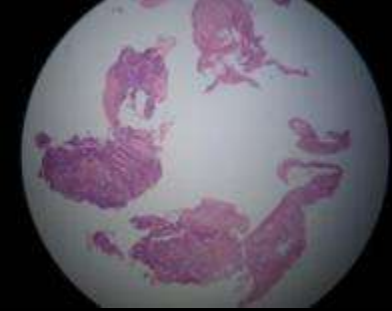
CK

LCA

CD56

SYN

Small cells , Crush artifact.



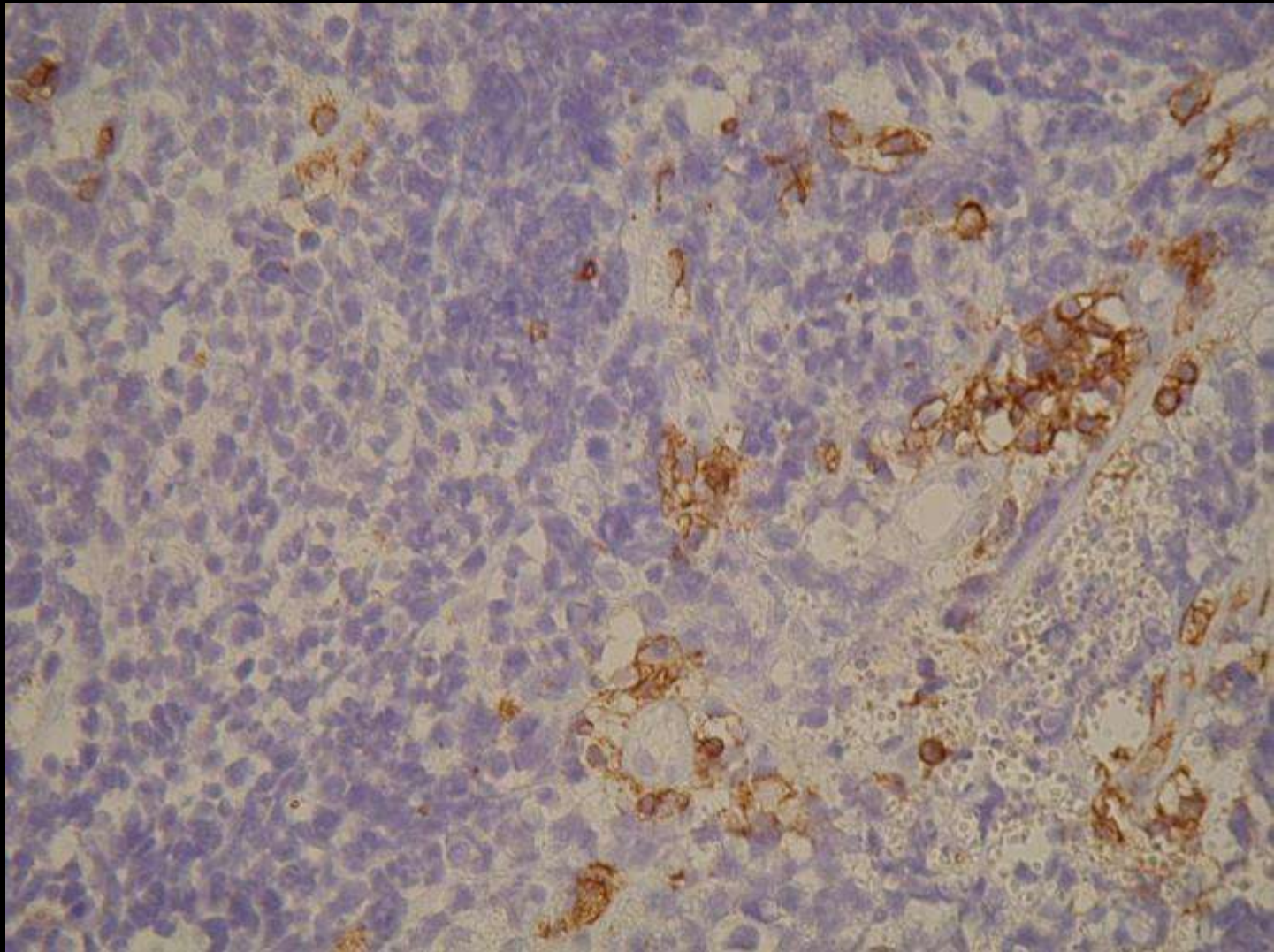
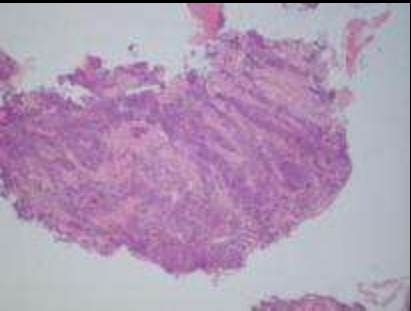
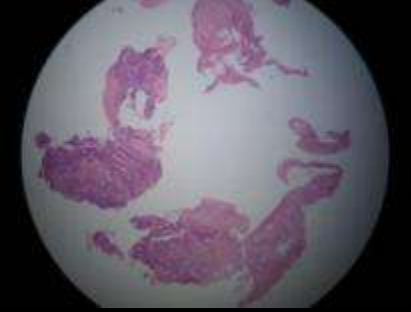
CK

LCA

CD56

SYN

Paranuclear dot-like positivity



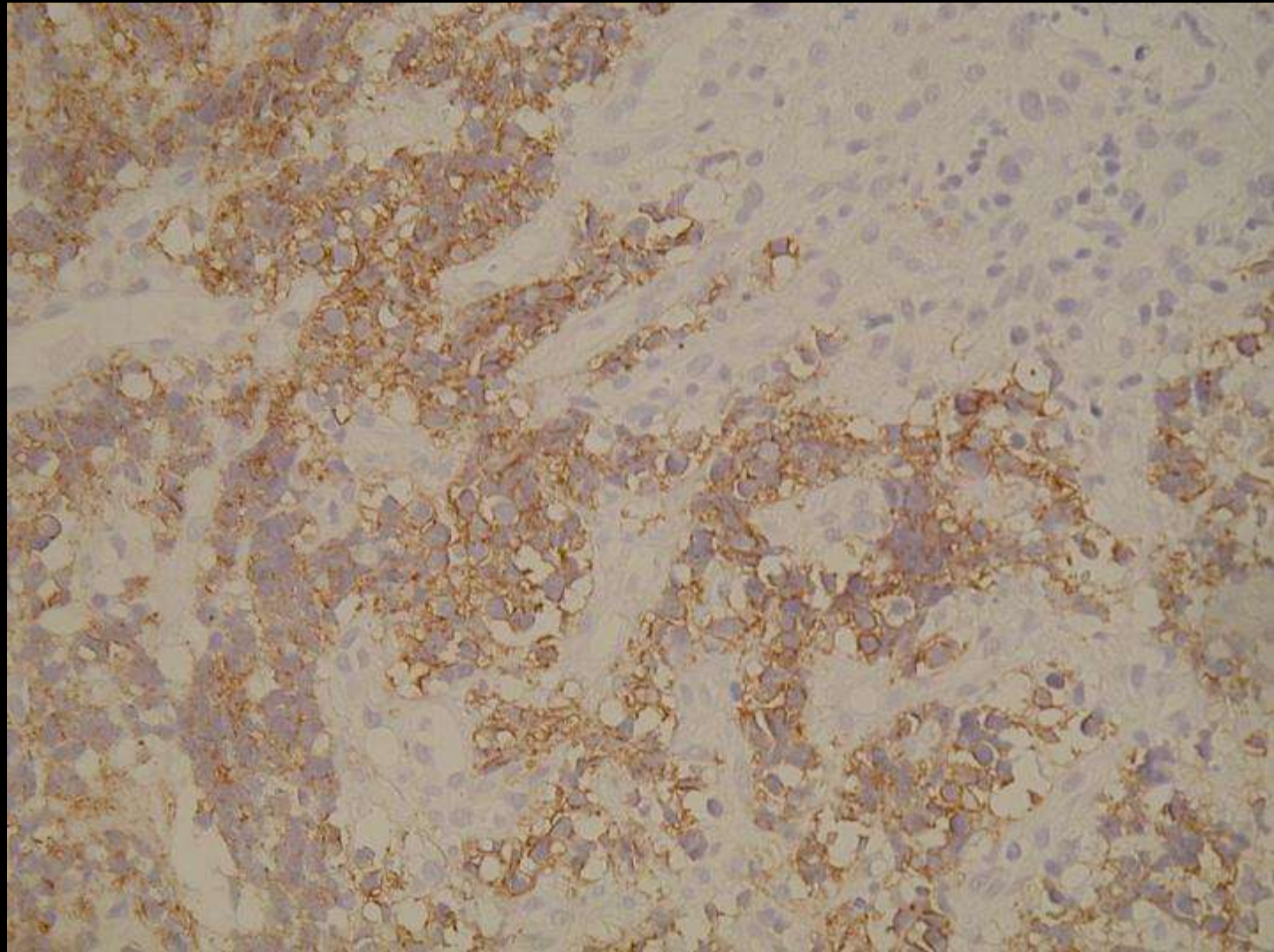
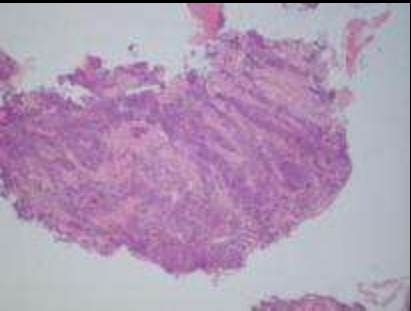
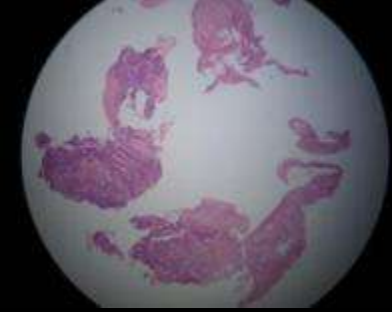
CK

LCA

CD56

SYN

Membranous positivity in lymphoid cells



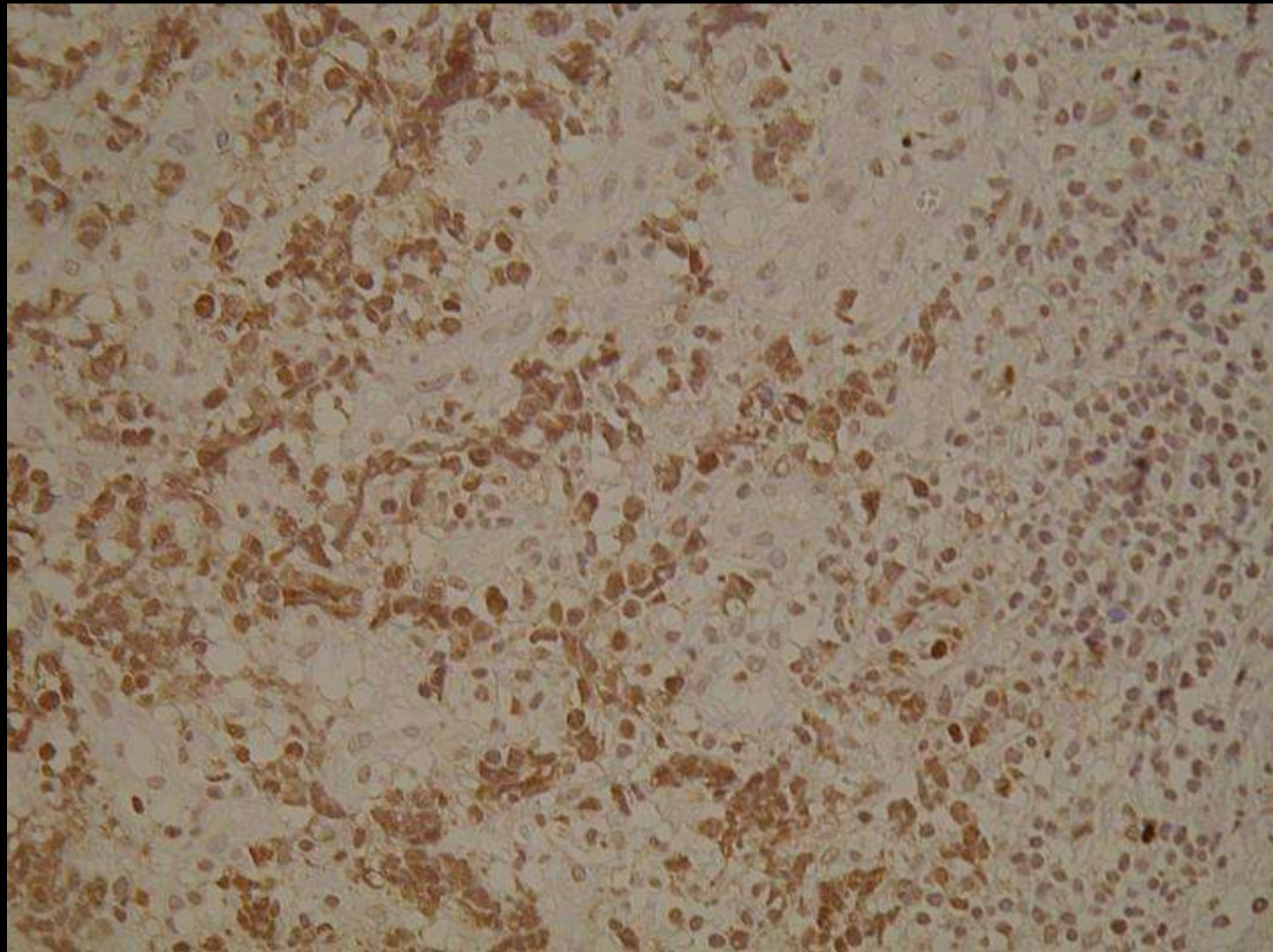
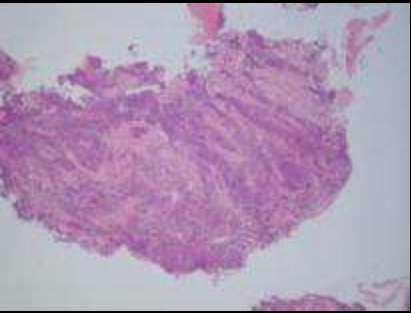
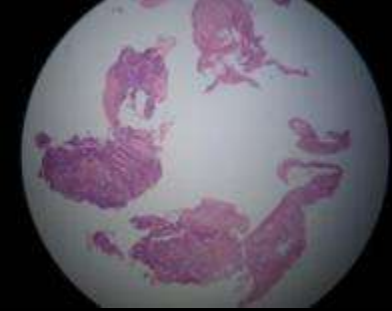
CK

LCA

CD56

SYN

Membranous positivity



CK

LCA

CD56

SYN

Diffuse cytoplasmic positivity

Diagnosis »

Small Cell Lung Carcinoma