

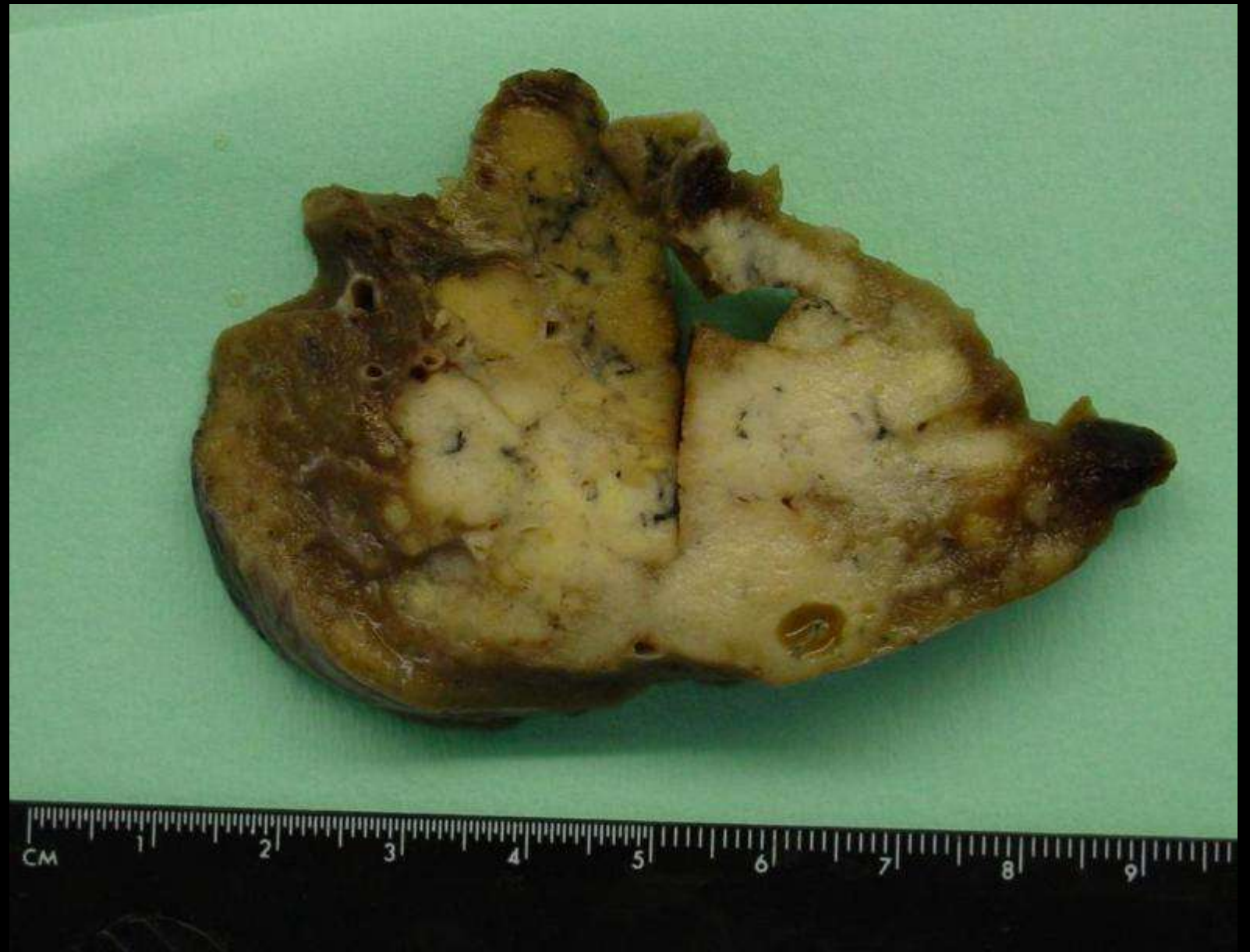Lung tumor

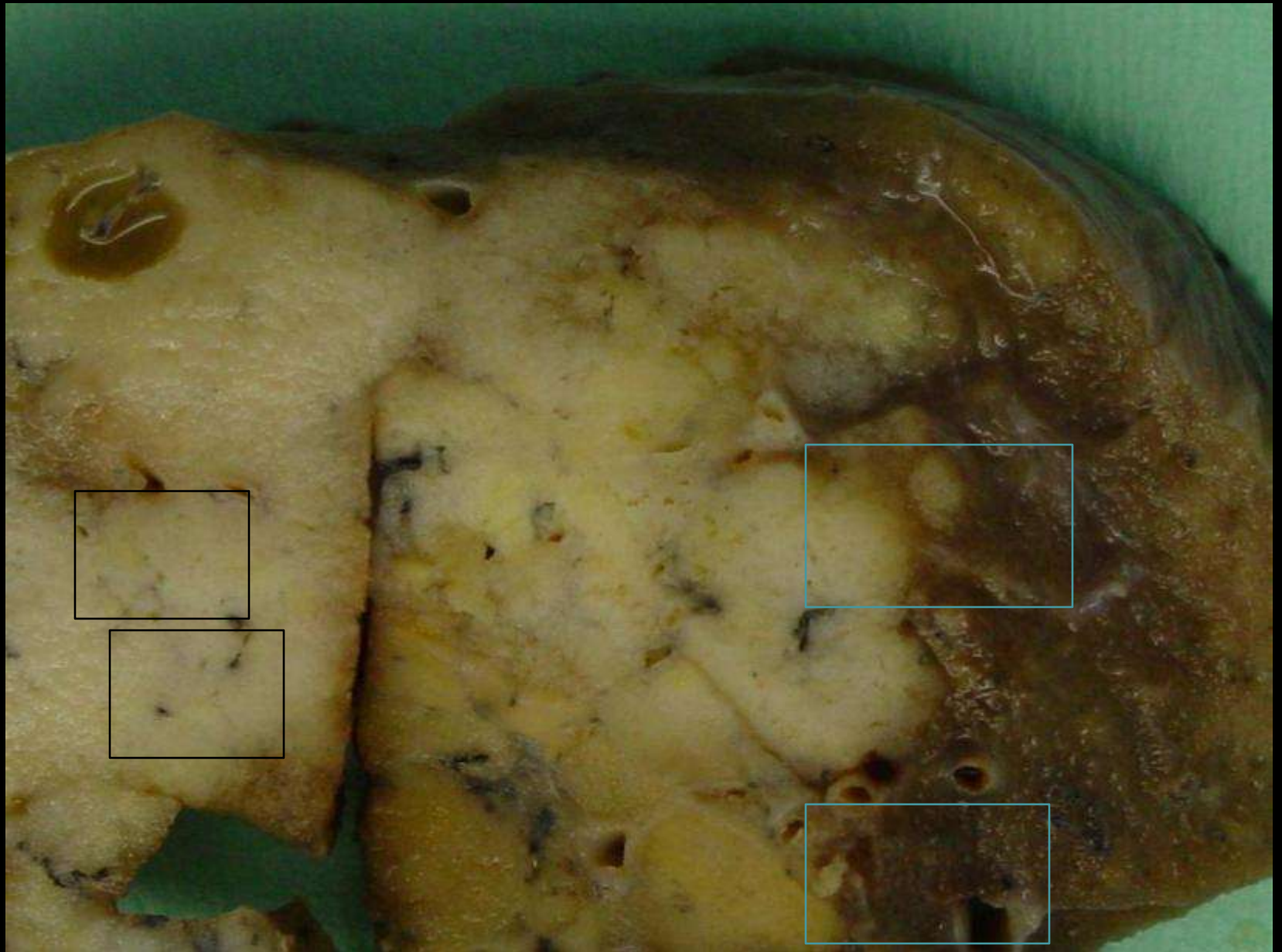
Lobectomy

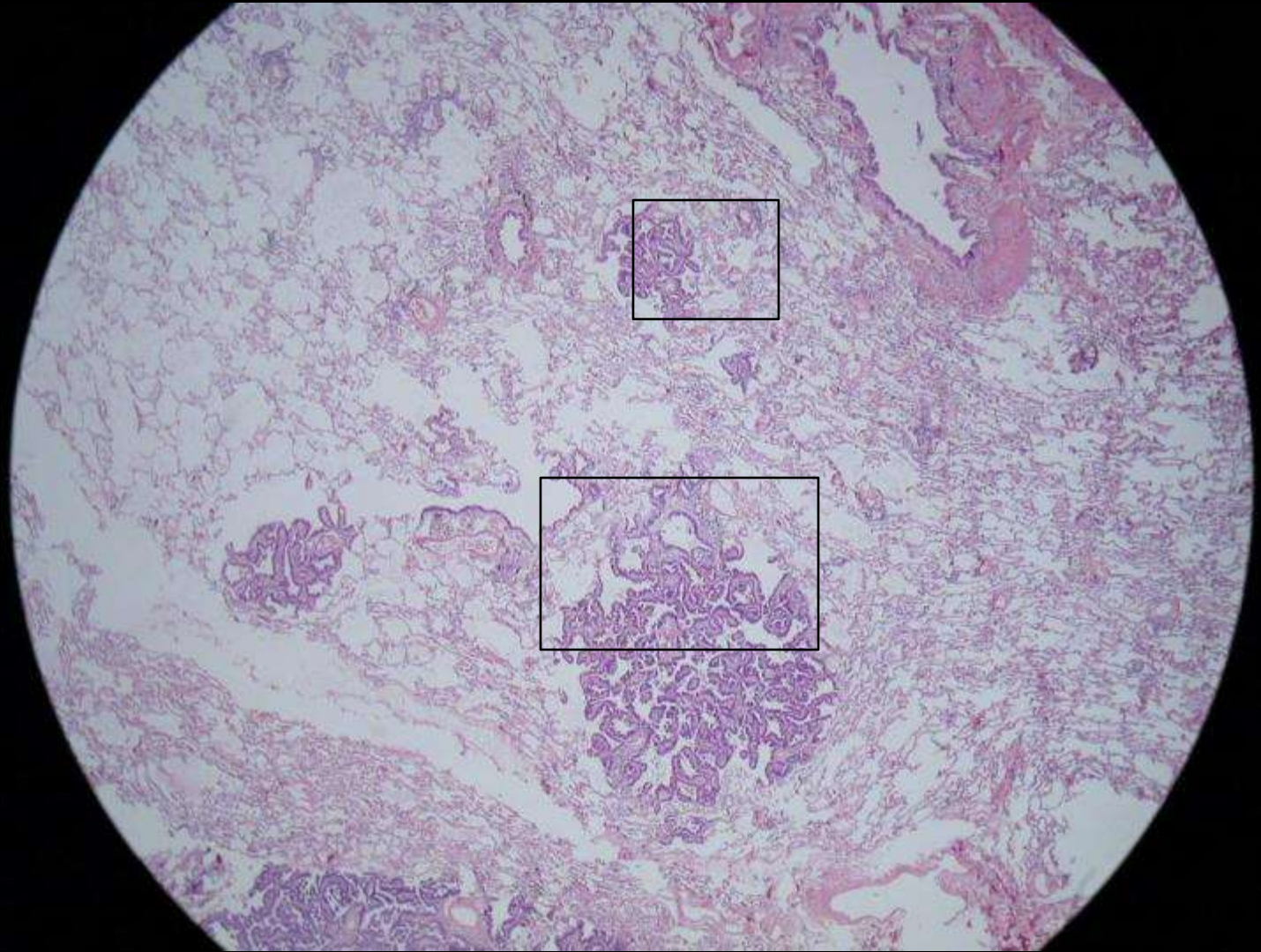
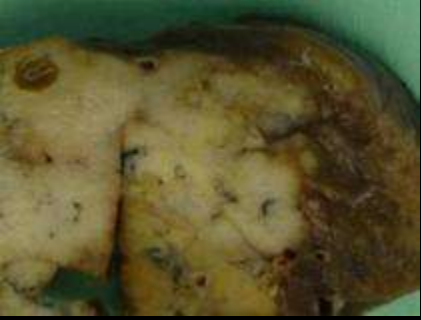Gérard ABADJIAN

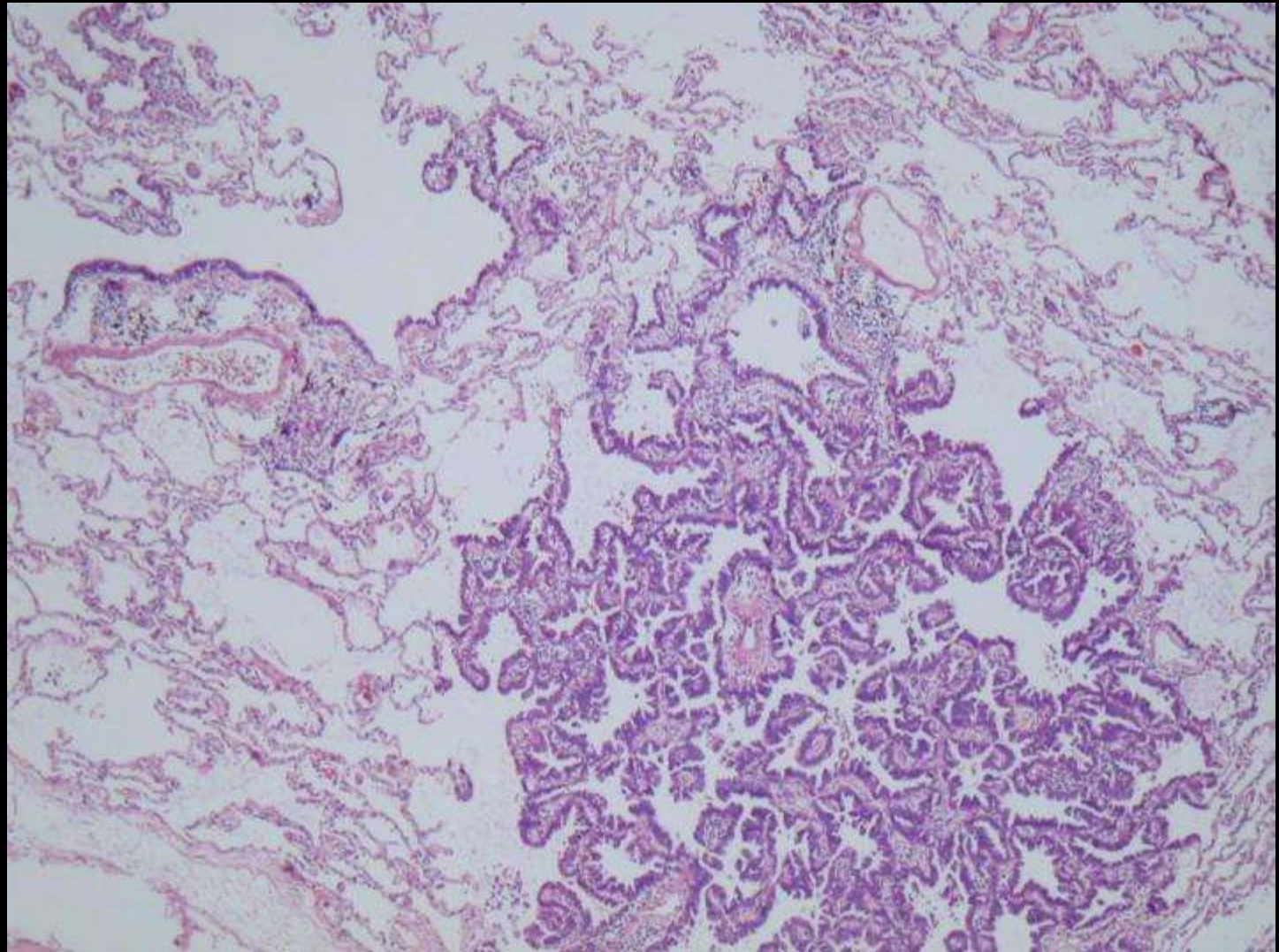
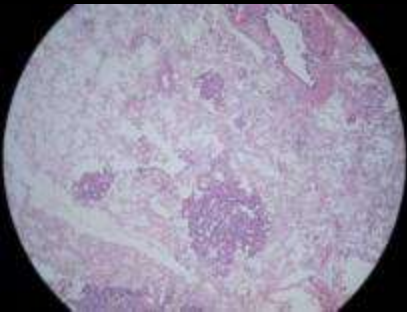
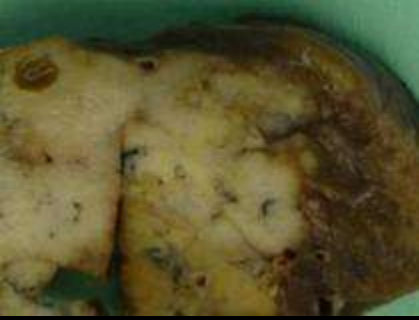May 2008

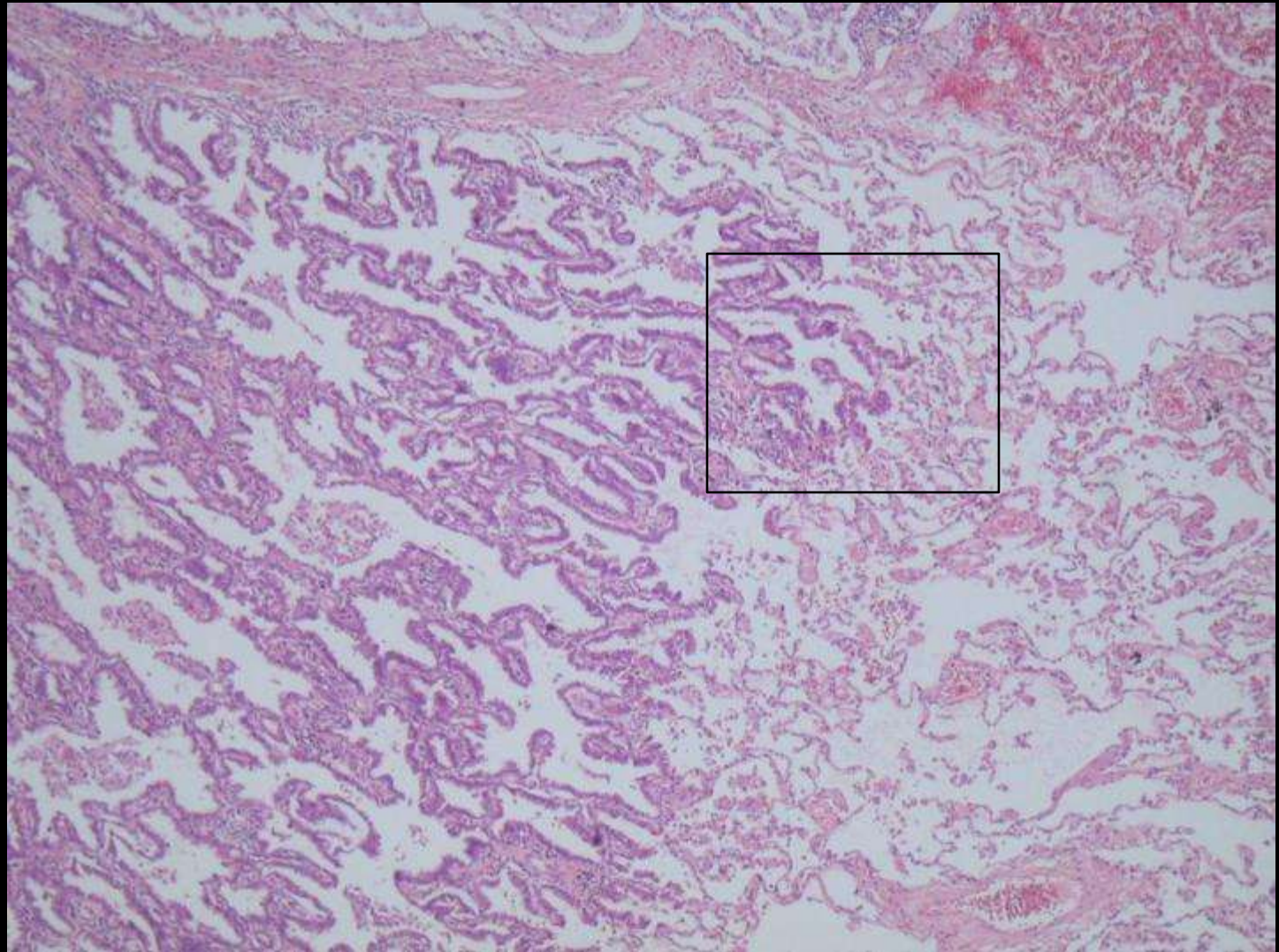
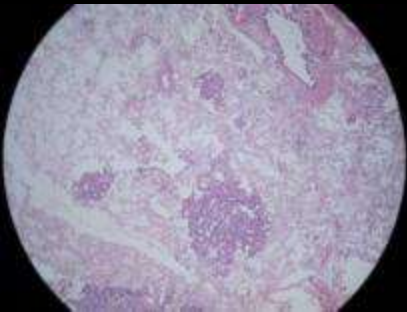
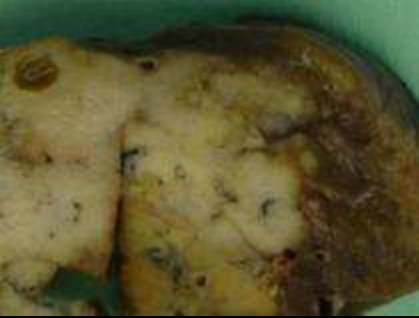Diagnosis in the last slide

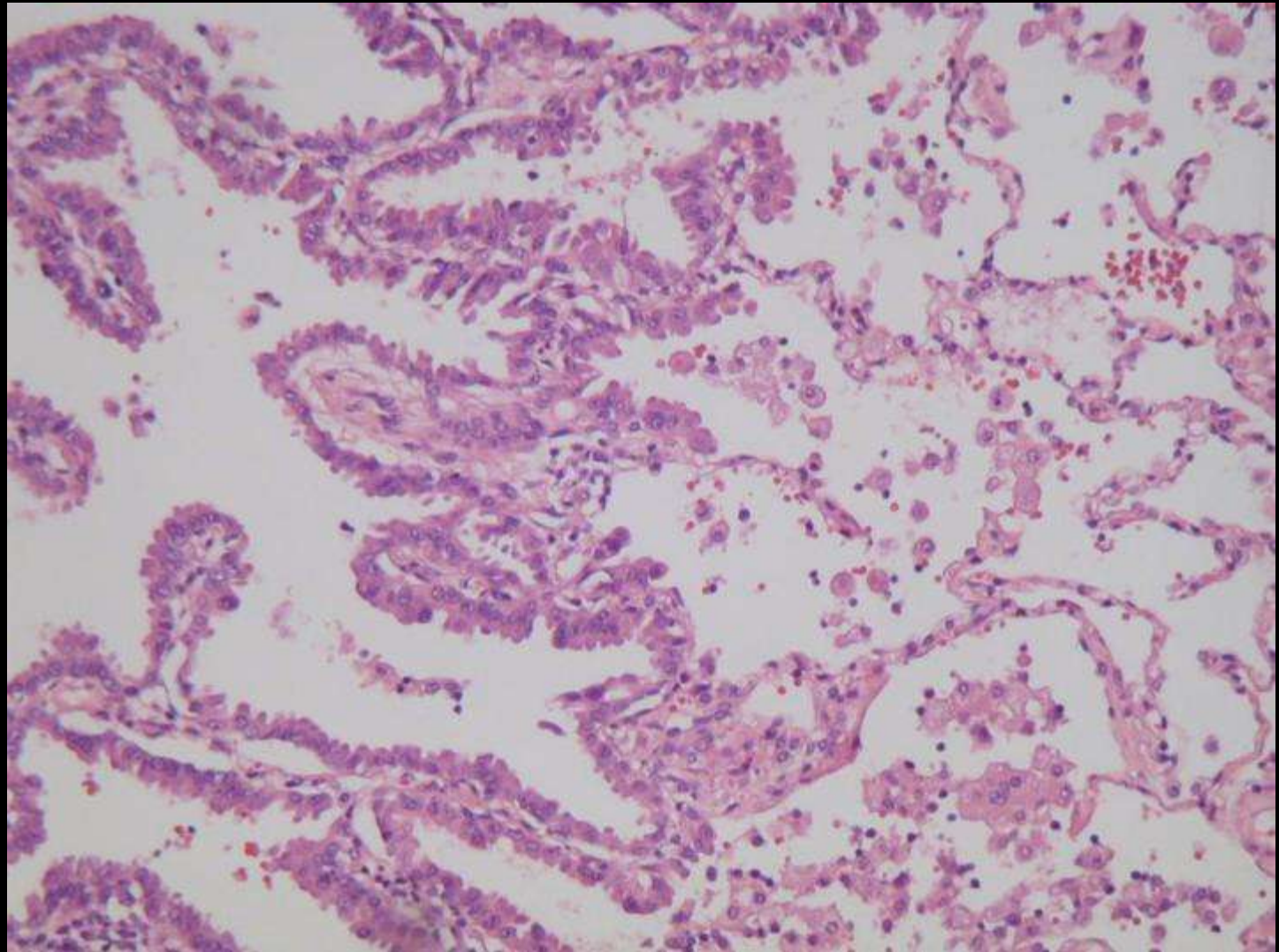


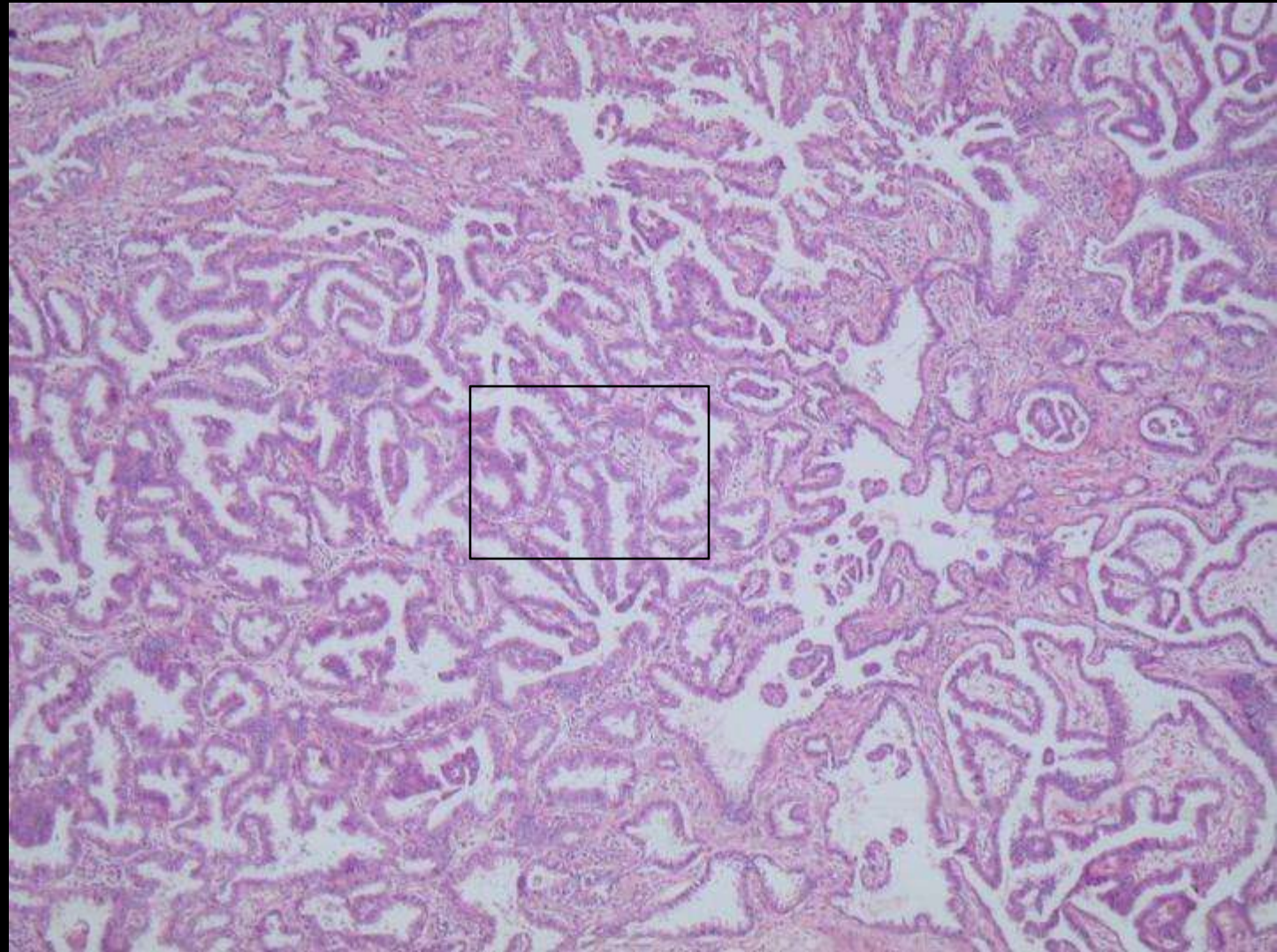


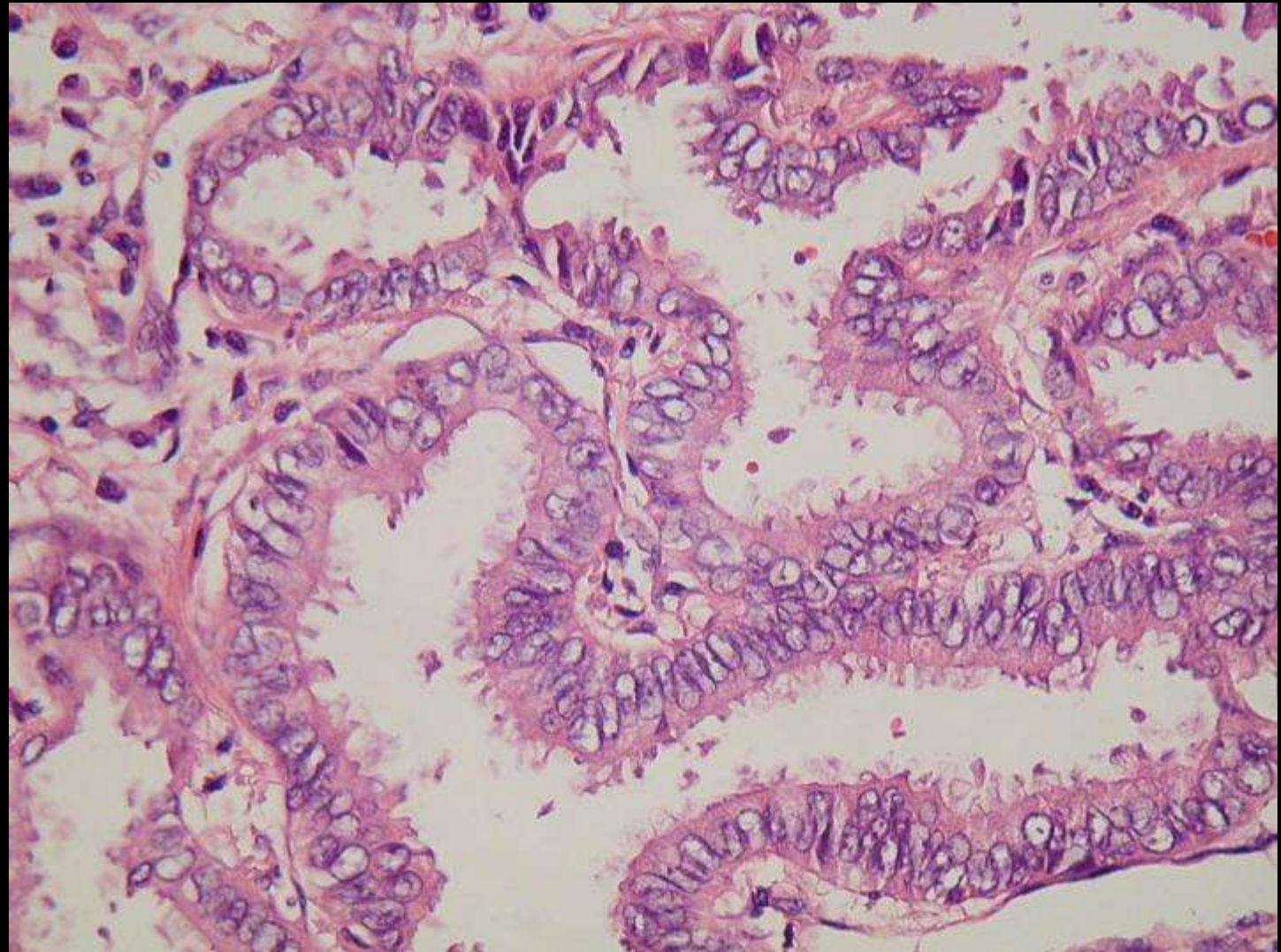




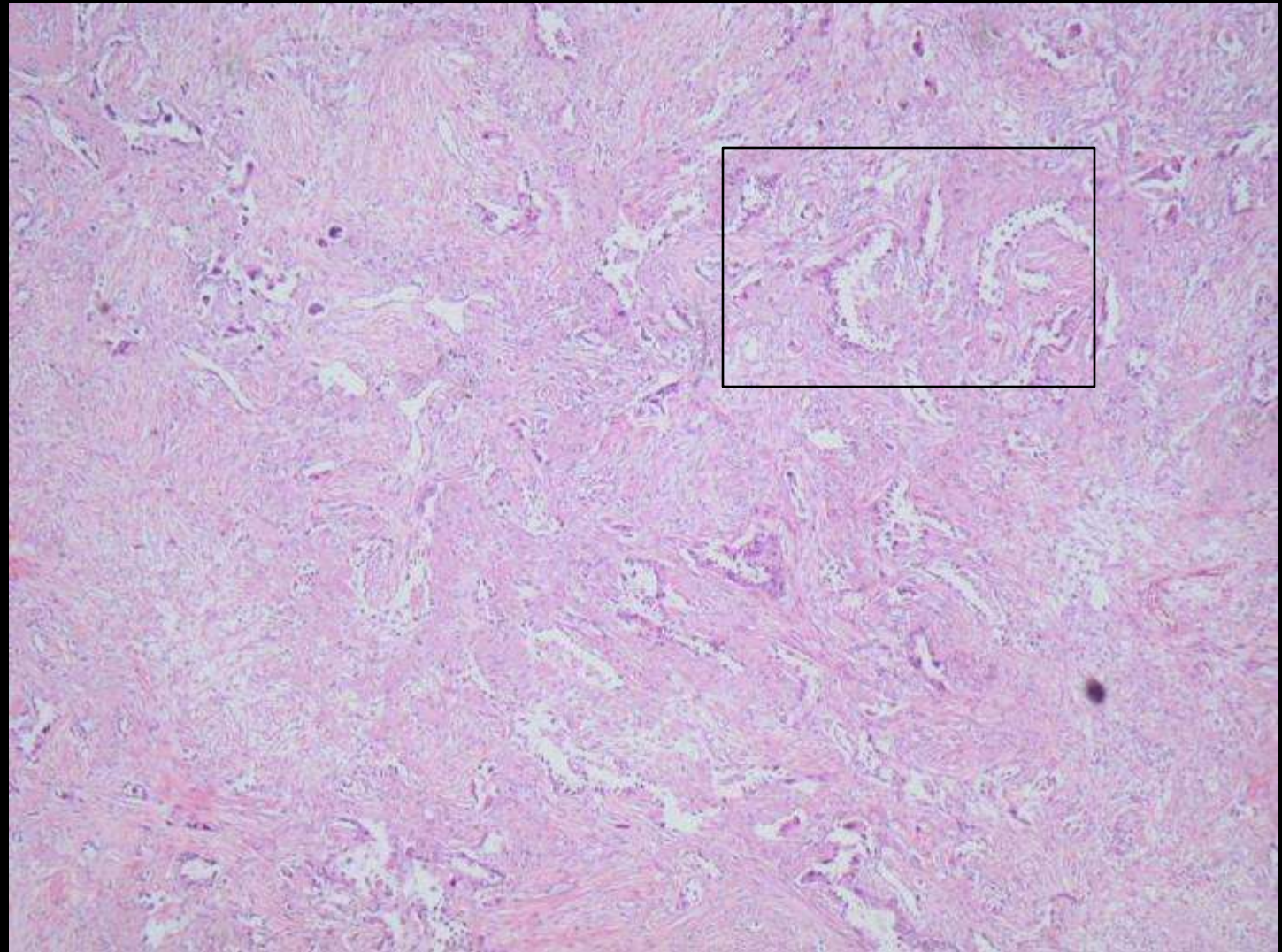


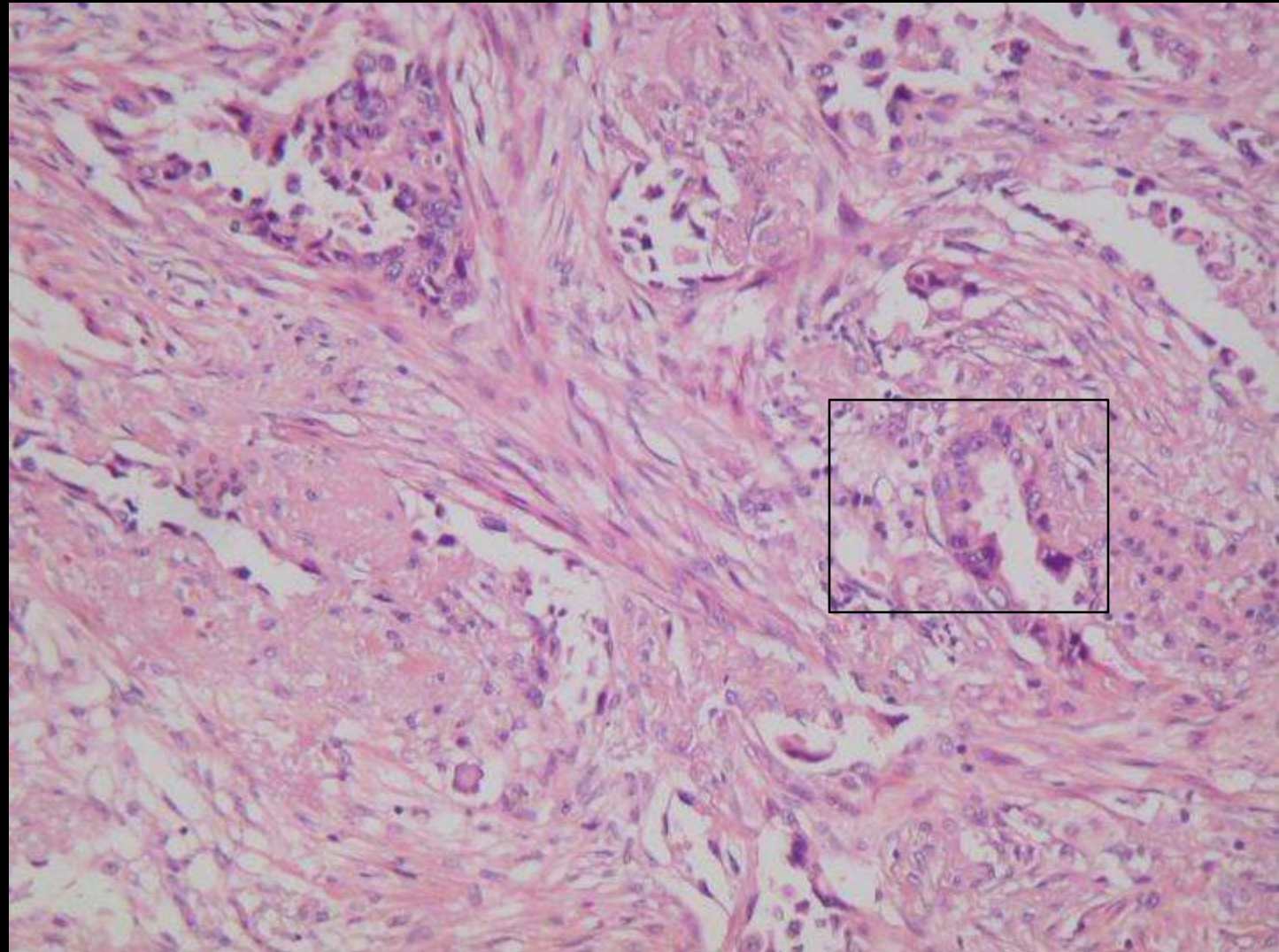


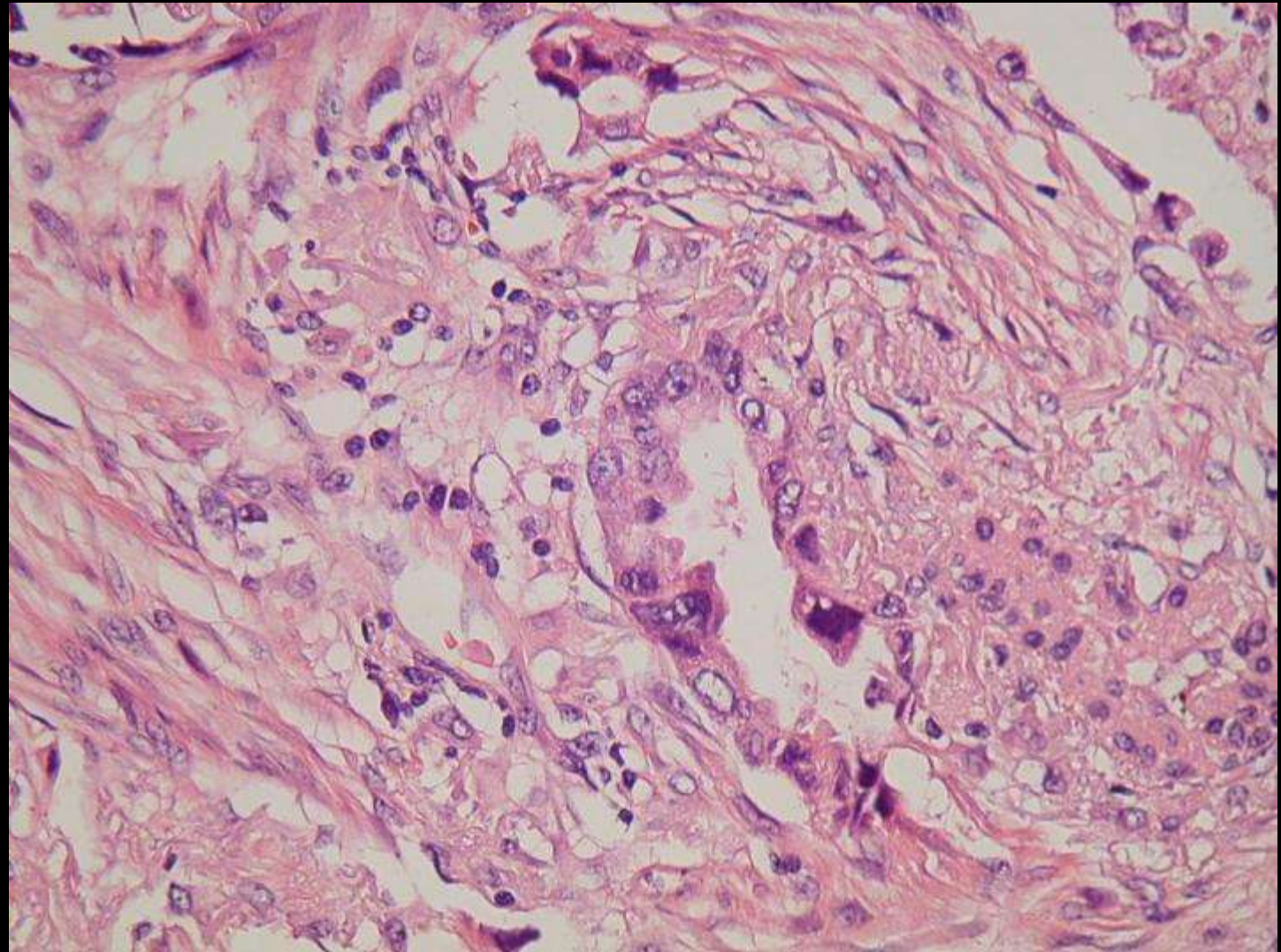


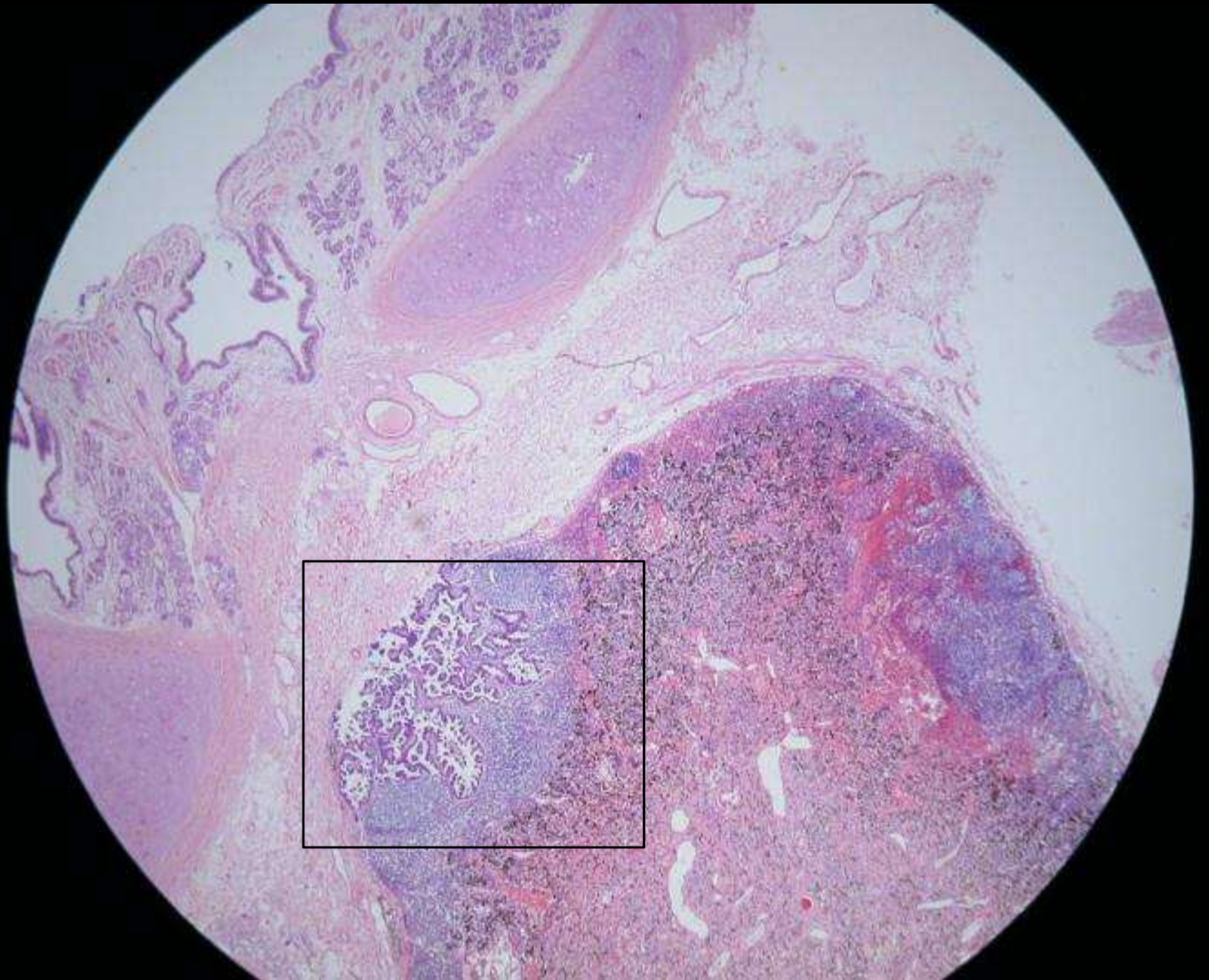


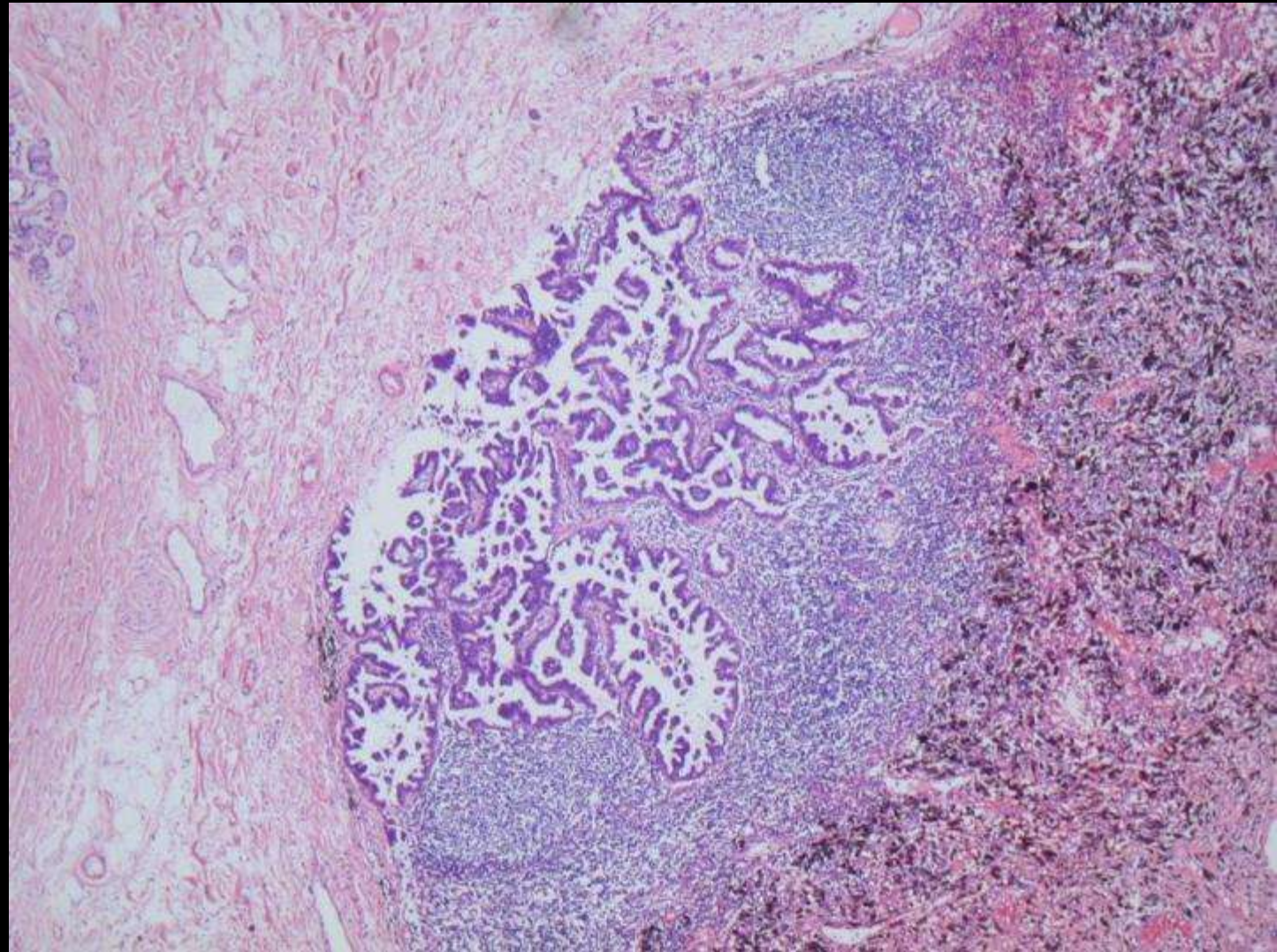
TTF1

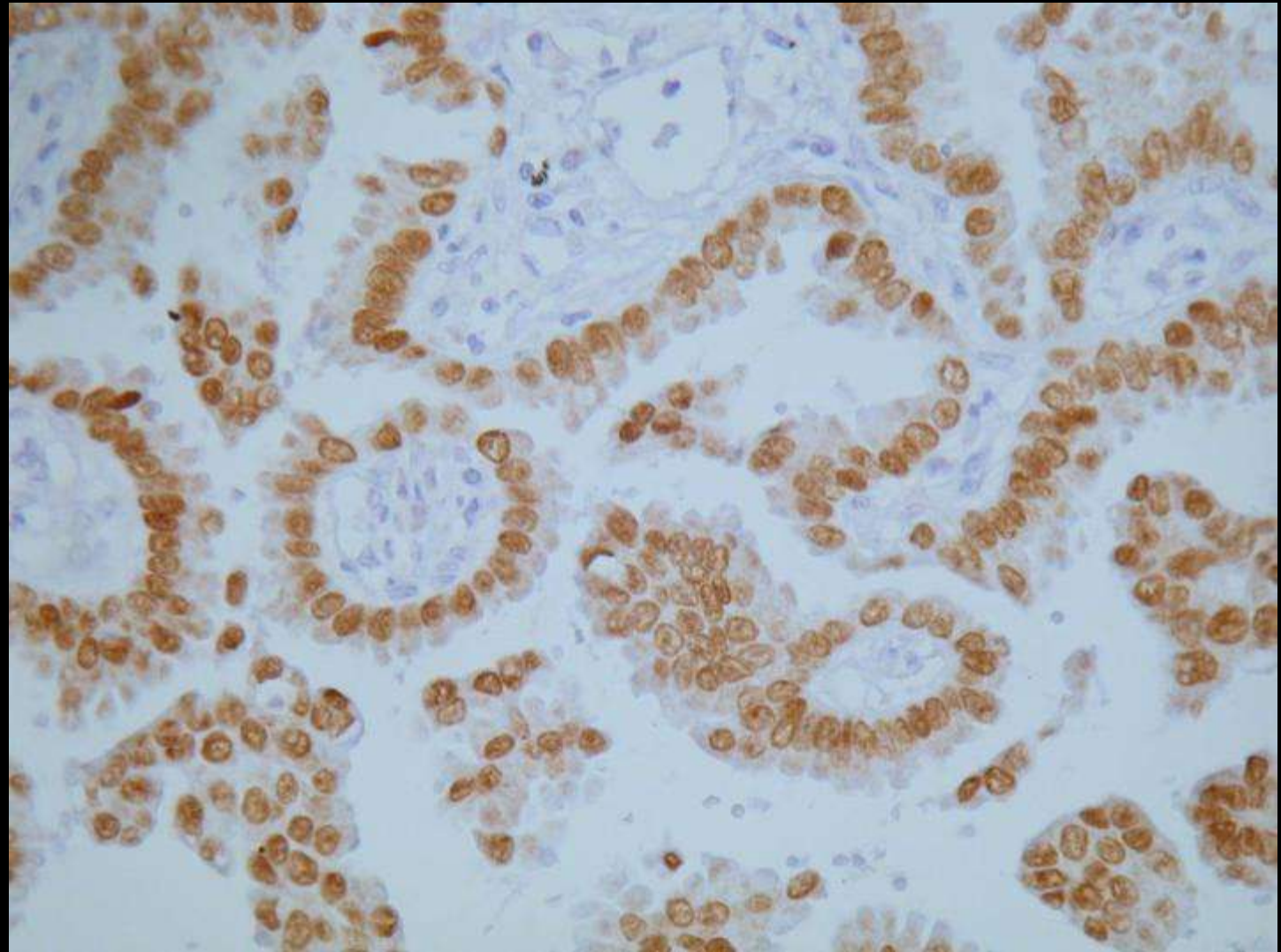












Diagnosis »

Lung, lobectomy:

Adenocarcinoma, NOS , measuring 4 x 3.5 cm.

Grade II (moderately differentiated)

Tumor extends to but does not invade visceral pleura .

Bronchial surgical margin negative.

Intrapulmonary peribronchial lymph node metastasis.

pT2 N1